
MINOR HEAD INJURY IN THE PEDIATRIC PATIENT

Kimberly S. Quayle, MD

Minor head injuries among children are a common reason for physician visits, either in emergency departments or in general practices.^{3,37} In all settings, the physicians caring for these children must decide on the appropriate management, including decisions about the role of imaging studies and admission to the hospital. Considerable controversy exists in the published reports about managing children with minor head injuries. This review discusses the literature and provides suggested recommendations for the management of head-injured children.

EPIDEMIOLOGY OF HEAD INJURIES IN CHILDREN

Six hundred thousand children are seen in US emergency departments for evaluation of head injuries each year, and 250,000 are admitted to hospitals for additional treatment or observation.²⁹ Physicians in private offices or clinics see many additional patients with head injuries.^{46,60} The admission rates for children with head injuries are 1.5-fold to twofold higher than that for the general adult population, but the attendance rate in emergency departments is several-fold higher among young children,³¹ possibly indicating the heightened concern that parents have about relatively minor injuries in young children. The incidence of hospital admissions for head-injured children aged 0 to 14 years was 185 per 100,000 in 1981.³⁵ The incidence was highest in adolescents and young adults, with peak incidence occurring at 15 to 19 years.³⁵ Until the age of 5 years, the incidence of head injuries is similar among boys and girls, but after 5 years, the incidence among boys is higher.^{1,34} The highest rates of head injuries for all ages are reported among those in lower socioeconomic groups.¹

The causes of head injuries among children vary by age. The leading cause

From the Department of Pediatrics, Washington University School of Medicine; and Pediatric Transport Team, St. Louis Children's Hospital, St. Louis, Missouri

of severe or fatal head injuries is motor vehicle collisions for all age groups, whereas falls are the leading cause of all injuries.^{3, 67} In very young children, falls are the predominant cause of head injury, whereas child abuse causes a significant number of severe injuries. Among school-aged children, pedestrian-motor vehicle collisions and bicycle-related injuries are more common causes of severe injuries. In adolescents, motor vehicle collisions replace falls as the leading cause of all injuries, followed by assault and sports-related injuries.

DEFINITION OF MINOR HEAD INJURY

Traditionally, patients with minor head injuries have been defined as those with a history of acute injury, a Glasgow Coma Scale (GCS; Table 1) score of 13 to 15, and no focal neurologic deficits. Several studies have reported the occurrence of intracranial injuries among patients with injuries meeting the definition of *minor head injury*, especially those with GCS scores of 13 or 14.^{11, 15, 22, 27, 44, 47, 54} In addition, reports of children who "talk and die" demonstrate that severe deterioration or even death can occur in children after a period of lucidity.^{30, 59} Although most children who seek care for minor head injuries do not have intracranial injuries, these reports have fueled the controversy about the management of children with minor head injuries. A review of the literature can address several clinical dilemmas, such as the choice of imaging modalities for minor head injuries, the identification of predictive clinical criteria for intracranial injury, and the incidence of intracranial injuries among neurologically normal children.

IMAGING MODALITIES

As early as 1971, several investigators examined the practice of obtaining skull radiographs in all children with head injuries.^{4, 14, 28, 48} Harwood-Nash et

Table 1. GLASGOW COMA SCALE

Sign	Score
Best motor response	
Obeys verbal commands	6
Localizes pain	5
Flexion withdrawal to pain	4
Abnormal flexion to pain (decorticate posturing)	3
Extension to pain (decerebrate posturing)	2
None	1
Best verbal response	
Oriented	5
Confused conversation	4
Inappropriate words	3
Incomprehensible sounds	2
None	1
Eye opening	
Spontaneous	4
To speech	3
To pain	2
None	1

al²⁸ emphasized the occurrence of intracranial injury without the presence of skull fracture, findings that have been substantiated numerous times since,^{36, 38, 39, 44} but the presence of a skull fracture indicates that a significant force has been applied to the calvarium. Furthermore, studies have shown that the presence of a skull fracture increases the likelihood of the presence of an intracranial injury.^{7, 10, 11, 22, 44, 62}

Since the late 1970s, CT has become the imaging modality of choice to acutely identify intracranial injuries in head-injured patients.^{18, 65, 66} Although magnetic resonance (MR) imaging studies have shown evidence of subtle intracranial injury in patients with minor head injuries who have normal head CT scans,^{17, 41} their limited availability in acute-care settings prevents their routine use. CT may also not be readily available at all facilities, may require the sedation of young, uncooperative patients, and always requires skilled interpretation. Although some investigators continue to recommend skull radiographs or CT for the routine screening of head-injured patients,^{10, 27, 56, 61, 62} most advocate the selection of patients at higher risk for intracranial injury.^{12, 15, 21, 38, 40, 42, 44, 45, 52}

In 1987, the Masters et al⁴⁰ multidisciplinary panel proposed a set of recommendations for the use of skull radiography and CT for patients with head injuries. The panel identified asymptomatic patients or those with headaches, dizziness, scalp lacerations, hematomas, and abrasions as the low-risk group and recommended no radiographic studies for patients who met these criteria. Moderate-risk and high-risk categories were also described, with consideration for CT in the moderate group and with recommended CT in the high-risk group. Skull radiographs were considered rarely helpful, only in the moderate-risk group. In these recommendations, children and adults were grouped together in the management strategies, except for infants and toddlers younger than 2 years of age who were assigned to the moderate-risk group unless the injury was trivial. The investigators did not define *trivial injury*. The panel then applied their management strategy prospectively for validation. Of the 5254 patients who met the low-risk-group criteria, 0.4% had skull fractures and none had intracranial injuries identified, but only approximately half of the patients underwent radiography.

PREDICTIVE CLINICAL CRITERIA

Additional studies have been performed to attempt identification of clinical features, such as symptoms or signs related to the head injury, which might predict intracranial injuries in children. Until recently, most were small, retrospective series that studied children who had undergone CT.^{7, 29, 47} Hennes et al²⁹ retrospectively studied 55 children and identified altered mental status, evidence of increased intracranial pressure, seizures, and focal deficits as predictors of intracranial injury. Rivara et al⁴⁷ retrospectively looked at 98 children and described an abnormal GCS score, altered consciousness, and focal neurologic abnormality as predictive of intracranial injury.

Two more recent studies prospectively examined children who had undergone CT for the evaluation of head injuries.^{15, 45} Dietrich et al¹⁵ reported loss of consciousness, amnesia, GCS score of less than 15, and neurologic deficit as significantly associated with intracranial injury. Ramundo et al⁴⁵ described suspicion of child abuse, focal motor deficit, and pupillary asymmetry as predictors of intracranial injury.

Quayle et al⁴⁴ performed a prospective study of 321 head-injured children who met predetermined selection criteria and identified altered mental status,

neurologic deficits, skull fracture, signs of a basilar skull fracture, and seizure as independent predictors of intracranial injury. The presence of neurologic deficits was the only predictive clinical feature common to all of these studies.

None of these prospective studies found clinical criteria predictive of all intracranial injuries. Nineteen percent of children with intracranial injuries in the study by Quayle et al⁴⁴ failed to demonstrate any of the predictive clinical findings. Symptoms such as headache, vertigo, vomiting, and brief loss of consciousness and findings such as scalp lacerations and hematomas are not predictive of intracranial injury. Although these features occur commonly in patients who have intracranial injuries, they also occur commonly in patients who do not.

INTRACRANIAL INJURIES IN NEUROLOGICALLY NORMAL CHILDREN

Brain injuries occur in patients without worrisome clinical findings. Several recent studies have described the occurrence of intracranial injuries among children who are alert and without neurologic deficits.^{15, 27, 44, 54} Dietrich et al¹⁵ prospectively studied 322 children with head injuries and found 5% who were neurologically intact but had intracranial injuries. Twenty-eight percent of all subjects with intracranial injuries were neurologically intact, with GCS scores of 15. The prospective study by Quayle et al⁴⁴ of head-injured children showed that 6% of children were neurologically normal but also had intracranial injuries. Five (2%) of the neurologically normal children in this study underwent surgery, including one child with an epidural hematoma and four children with depressed skull fractures. Fifty-nine percent of all subjects with intracranial injuries were alert and had no focal neurologic deficits. Schunk et al⁵⁴ reviewed the charts of 313 children with normal neurologic examinations who underwent CT scans and reported that 4% of the children had intracranial injuries. Four children (1%) underwent surgery, including three children with epidural hematomas and one with an orbital fracture. The 6-year prospective study by Hahn et al²⁷ of children with head injuries admitted to hospitals found that 13.4% of children were alert at the time of initial examination but subsequently underwent surgery. This same study described that 7.1% of children with GCS scores of 15 also had mass lesions. Davis et al¹² described that none of 49 neurologically intact children older than 2 years with isolated head injuries had intracranial hemorrhage. The findings from all of these studies suggest that intracranial injury may occur in 3% to 7% of symptomatic, head-injured children who are neurologically normal.

SPECIAL CONSIDERATIONS

Infants and Toddlers

Although head injury is a common occurrence in infants and toddlers, they have been excluded from many of the studies addressing head injuries among children.^{12, 29, 47} Because of their age and inability to communicate verbally, many believe that infants and young children must be managed differently than older children. Masters et al⁴⁰ placed infants and children younger than 2 years in the moderate-risk category unless the injury was trivial. Pietrzak et al⁴³ and Ros and Cetta⁵¹ recommend a low threshold for radiographic imaging in these children. Leonidas et al³⁶ suggested that all infants younger than 1 year who present after

acute head trauma should undergo skull radiography, and Ros and Cetta⁵¹ provide similar recommendations.

More recent studies also address the issue of head injuries in infants. Soft-tissue swelling of the scalp occurs commonly in infants with skull fractures. Shane and Fuchs⁵⁷ found that 98% of infants with skull fractures had "evidence of scalp trauma" in association with their skull fractures. Greenes and Schutzman²³ found that 96% of infants with isolated skull fractures had local findings of head injury, either swelling or palpable fracture. Although scalp hematomas were not predictive of intracranial injury in the study by Quayle et al,⁴⁴ they were predictive of skull fractures in infants younger than 1 year. Kleinman and Spevak³³ identified soft-tissue swelling, demonstrated by CT scan, in all cases of acute skull fracture. These studies suggest that the presence of scalp hematomas in infants indicates the possibility of underlying skull fractures.

The presentation of intracranial injury in infants may be subtle. Greenes and Schutzman²⁴ describe 19 of 101 (19%) infants who had intracranial injuries without other symptoms. Eighteen of 19 infants with occult intracranial injuries had scalp contusions or hematomas, and 18 of 19 had skull fractures. Occult intracranial injuries were more common in infants younger than 6 months of age. In the 16 neurologically normal children with intracranial injury described by Quayle et al,⁴⁴ five were infants who had a scalp contusion or hematoma, but no other symptoms. All of the infants with intracranial injuries in this study also had associated skull fractures. Data suggest that asymptomatic infants with scalp hematomas should undergo screening with skull radiographs, and infants with any symptoms following head injury should undergo head CT.

Child Abuse

Caffey⁸ and Kempe et al³² provided the classic descriptions of nonaccidental head injuries among infants and young children. Since that time, inflicted head injury has been recognized as the most common cause of injury-related deaths in infants.^{6, 20} In addition, nonaccidental head trauma is common in infants hospitalized for their injuries. In the prospective study by Duhaime et al¹⁹ of head-injured children younger than 2 years, 24% of the injuries were presumed inflicted. Billmire and Myers⁶ retrospectively studied head-injured infants younger than 1 year of age and found that 64% of the head injuries and 95% of severe intracranial injuries were the result of child abuse.

The classic constellation of head injuries in infants with shaken-impact syndrome includes subdural and subarachnoid hematomas and retinal hemorrhages. Previous reports have documented a strong association between subdural hematomas and abuse.^{19, 26, 58} Shugerman et al⁵⁸ reported that only 6% of young children with epidural hematomas had been abused, compared to 47% of those with subdural hematomas, but infants with isolated skull fractures or other intracranial injuries may also be victims of nonaccidental trauma. All infants with unexplained head injuries or injuries with a history insufficient to explain the findings on physical examination should be considered possible victims of child abuse. Additional information, including social service consultation, ophthalmologic examination, and skeletal surveys, may be useful. Retinal hemorrhages occur in patients during severe accidental trauma, but are most commonly encountered in patients with inflicted injuries.^{19, 64} In cases in which child abuse is suspected, skull radiographs can provide useful information to document the presence of fractures.

Growing Skull Fractures

Growing skull fractures, or leptomeningeal cysts, are rare complications of skull fractures, occurring almost exclusively in children younger than 3 years.²⁵ A growing skull fracture occurs when a fracture is accompanied by a dural tear. As time progresses, an enlargement of the fracture occurs, with a palpable cranial defect. Progressive brain damage can occur if the defect is not detected and repaired. Children younger than 3 years with skull fractures should be examined 2 or 3 months after their injuries occur to screen for growing fractures, but some case reports demonstrate late occurrences several years later.²⁵ The incidence is unknown, but Shane and Fuchs²⁷ reported that three (3%) infants with skull fractures developed growing fractures. In two of three cases, the fractures were diastatic at presentation.

DISPOSITION FOLLOWING HEAD INJURY

Intracranial injuries can have delayed presentation. A 1984 British study by Sainsbury and Sibert⁵³ described that 37% of children with intracranial injuries presented more than 24 hours after the traumatic event. Schutzman et al⁵⁵ reported that 26% of children with epidural hematomas were diagnosed upon follow-up visits. None of these children underwent CT scans on the initial visit.

Recent reports suggest that children with normal head CT scans can be safely discharged from the emergency department. Davis et al¹³ described 400 children with GCS scores of 13 to 15 and normal head CTs. Four children (1%) were readmitted for neurologic reasons. One child taking warfarin developed a symptomatic subdural hematoma requiring surgical evacuation, one child developed a parenchymal contusion requiring observation without surgery, and two others were admitted with concussive symptoms but normal repeat head CT scans. One of 300 children in the study by Schunk et al⁵⁴ returned with a parenchymal contusion after an initially normal head CT. None of the 227 children discharged from the emergency department in the study by Quayle et al⁴⁴ returned to the hospital after initially normal head CT scans. In two additional studies, the charts of children hospitalized for minor head injuries but with normal head CT scans were reviewed, and investigators found none who developed complications.^{49, 50} Children with normal head CT scans and normal neurologic examinations can be safely discharged, provided that reliable caretakers can observe these children at home and return them for persistent or progressive symptoms.

LONG-TERM OUTCOME AFTER MINOR HEAD INJURY

The long-term impact of subtle, intracranial injuries not necessitating surgery on the neuropsychologic development of children is controversial. Severe head injuries clearly cause significant disabilities in children as they do in adults, but the impact of minor head injury is less clear. DiScala et al¹⁶ described children with impairments of daily living functions, cognition, and behavior after minor head injury. Casey et al⁹ discovered transient functional and behavioral problems in children after minor head injury. Other reports found no significant neurobehavioral impairments in children with mild head injuries.^{2, 5} Studies that screened for preexisting cognitive, behavioral, and developmental impairments tended to find less morbidity after injury than studies without careful preinjury assessment.²

RECOMMENDATIONS FOR CHILDREN WITH MINOR HEAD INJURIES

Evaluation

Children who present with minor head injuries should undergo careful history taking and physical examinations. A patient's age, past medical history, medications, allergies, and immunizations should be noted. The circumstances of the injury should be understood, providing a clear picture of how the injury occurred. Any symptoms that develop after the injury should also be noted and might include loss of consciousness, vomiting, amnesia, headache, seizures, drowsiness, visual problems, irritability, or neck pain.

A thorough physical examination should follow. The general examination should include the assessment of a patient's cardiopulmonary status, vital signs, and weight and careful examination of the neck, chest, abdomen, and extremities, searching for any coexisting injuries. The head should be examined for the presence of scalp hematomas, contusions, abrasions, and lacerations. The presence of palpable skull depression and signs of a basilar skull fracture, such as raccoon eyes, Battle sign, cerebrospinal fluid drainage from the nose or ear, or hemotympanum, should also be noted.

Documenting a child's level of consciousness is the most important initial neurologic assessment.⁵³ The GCS has been almost universally used in the assessment of adults, but it is difficult to use in younger children because of their preverbal status. A useful description of mental status that can be applied to all ages is the AVPU method, in which patients are described as *alert*, responsive to verbal stimuli, responsive to painful stimuli, or *unresponsive*. The neurologic examination should also include the assessment of cranial nerve function, motor and sensory examination, deep tendon reflexes, and gait.

Imaging

Based on a review of the literature, recommendations for imaging studies in head-injured children follow (Fig. 1). Physicians should obtain head CT scans for head-injured children with altered mental status, focal neurologic deficits,

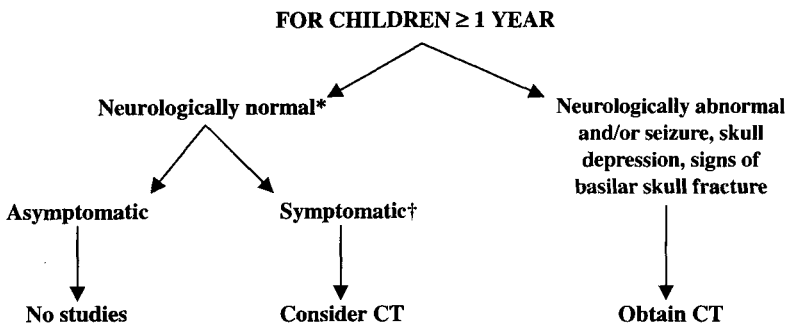


Figure 1. Imaging recommendations for children greater than or equal to 1 year of age. *Neurologically normal includes alert mental status and no focal deficits. †Symptomatic includes history of loss of consciousness, vomiting, headache, drowsiness, amnesia, or irritability.

signs of a basilar skull fracture, seizure, or palpable skull depressions. A head CT scan should be considered for neurologically normal children with a history of loss of consciousness, vomiting, headache, drowsiness, irritability, or amnesia. Careful observation of these children at home may be an alternative approach. Children in whom worsening symptoms develop or who have prolonged symptoms should return to medical care for re-evaluation and head CT scans. Neurologically normal children with unremarkable head CT scans may be discharged for observation at home. Neurologically normal children who are asymptomatic may also be discharged without undergoing imaging studies.

Skull radiographs are not recommended in most situations. If a head CT scan is available, then skull radiographs usually do not provide useful information, except for infants with hematomas or children with suspected nonaccidental trauma. If a head CT scan is not available, then skull radiographs may be helpful as screening tools. Children with known skull fractures should undergo head CT. Careful hospital observation may be an alternative approach when CT is not readily available. Skull radiographs provide important documentation for children with suspected nonaccidental trauma.

The recommendations for infants younger than 1 year of age differ from those for older children (Fig. 2). Any symptoms resulting from head injury in infants younger than 1 year should prompt strong consideration for head CT scans because infants with intracranial injuries may present with subtle signs and symptoms. Skull radiographs are recommended in alert, asymptomatic infants with scalp hematomas because, in infants, the presence of hematomas indicates the possibility of underlying skull fractures. Skull fractures in infants should warrant in-hospital observation, head CT scan, or both. Asymptomatic, neurologically normal infants without scalp hematomas may be discharged without undergoing imaging studies.

DISPOSITION

Criteria for hospital admission for observation and treatment of children with head injuries include intracranial injuries identified on head CT scan and

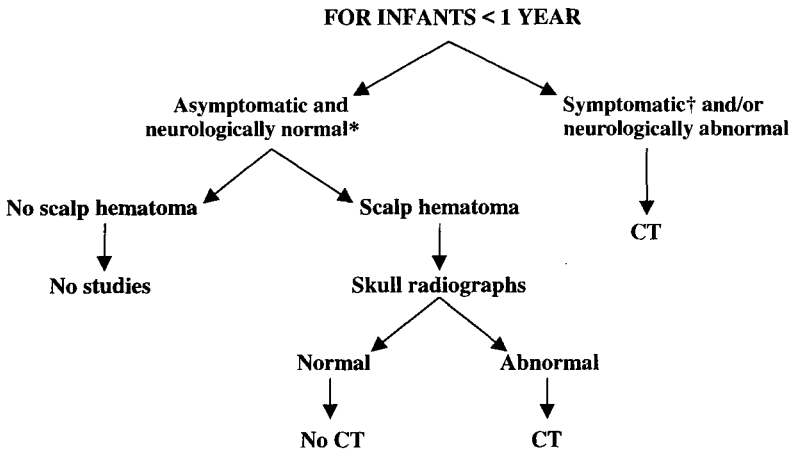


Figure 2. Imaging recommendations for infants less than 1 year of age. *Neurologically normal includes alert mental status and no focal deficits. †Symptomatic includes history of loss of consciousness, vomiting, drowsiness, or irritability.

neurologic abnormality accompanied by normal head CT scans. Children with suspected nonaccidental trauma, children without reliable caretakers or access to an emergency medical system, and children with known skull fractures but without head CT scans should also be admitted for observation. Caretakers of children who are discharged should receive careful instructions about indications for return to medical care. Worrisome findings include a persistent or progressive headache, persistent vomiting 8 hours after injury, drowsiness, weakness or clumsiness, blurry vision, poor balance when walking, change in the appearance of the pupils, behavioral changes, seizures, and watery or bloody discharge from the nose or ears. Symptomatic children and those with isolated skull fractures who are discharged should return to their physician for follow-up within 24 hours. Children younger than 3 years of age with skull fractures should return to their physician for additional follow-up 2 or 3 months after injury to be examined for cranial defects indicative of growing skull fractures.

References

1. Adelson PD, Kochanek PM: Head injury in children. *J Child Neurol* 13:2-15, 1998
2. Asarnow RF, Satz P, Light R, et al: The UCLA study of mild closed head injury in children and adolescents. *In* Broman SH, Michel ME (eds): *Traumatic Head Injury in Children*. New York, Oxford University Press, 1995, pp 117-146
3. Beattie TF: Minor head injury. *Arch Dis Child* 77:82-85, 1997
4. Bell RS, Loop JW: The utility and futility of radiographic skull examination for trauma. *N Engl J Med* 284:236-239, 1971
5. Bijur PE, Haslum M: Cognitive, behavioral, and motoric sequelae of mild head injury in a national birth cohort. *In* Broman SH, Michel ME (eds): *Traumatic Head Injury in Children*. New York, Oxford University Press, 1995, pp 147-164
6. Billmire ME, Myers PA: Serious head injury in infants: Accident or abuse? *Pediatrics* 75:340-342, 1985
7. Bonadio WA, Smith DS, Hillman S: Clinical indicators of intracranial lesion on computed tomographic scan in children with parietal skull fracture. *Am J Dis Child* 143:194-196, 1989
8. Caffey J: On the theory and practice of shaking infants: its potential residual effects of permanent brain damage and mental retardation. *Am J Dis Child* 124:161-169, 1972
9. Casey R, Ludwig S, McCormick MC: Minor head trauma in children: An intervention to decrease functional morbidity. *Pediatrics* 80:159-164, 1987
10. Chan KH, Yue CP, Mann KS: The risk of intracranial complications in pediatric head injury: Results of multivariate analysis. *Child Nerv Syst* 6:27-29, 1990
11. Dacey RG, Alves WM, Rimel RW, et al: Neurosurgical complications after apparently minor head injury: Assessment of risk in a series of 610 patients. *J Neurosurg* 65:203-210, 1986
12. Davis RL, Mullen N, Makela M, et al: Cranial computed tomography scans in children after minimal head injury with loss of consciousness. *Ann Emerg Med* 24:640-645, 1994
13. Davis RL, Hughes M, Gubler KD, et al: The use of cranial CT scans in the triage of pediatric patients with mild head injury. *Pediatrics* 95:345-349, 1995
14. DeVivo DC, Dodge PR: The critically ill child: Diagnosis and management of head injury. *Pediatrics* 48:129-138, 1971
15. Dietrich AM, Bowman MJ, Ginn-Pease ME, et al: Pediatric head injuries: Can clinical factors reliably predict an abnormality on computed tomography? *Ann Emerg Med* 22:1535-1540, 1993
16. DiScala C, Osberg JS, Gans BM, et al: Children with traumatic head injury: Morbidity and postacute treatment. *Arch Phys Med Rehabil* 72:662-666, 1991
17. Doezema D, King JN, Tandberg D, et al: Magnetic resonance imaging in minor head injury. *Ann Emerg Med* 20:1281-1284, 1991
18. Dublin AB, French BN, Rennick J: Computed tomography in head trauma. *Radiology* 122:365-369, 1977

19. Duhaime AC, Alario AJ, Lewander WJ, et al: Head injury in very young children: Mechanisms, injury types, and ophthalmologic findings in 100 hospitalized patients younger than 2 years of age. *Pediatrics* 90:179-185, 1992
20. Duhaime AC, Christian CW, Rorke LB, et al: Nonaccidental head injury in infants: the "Shaken-Baby Syndrome." *N Engl J Med* 338:1822-1829, 1998
21. Duus BR, Lind B, Christensen H, et al: The role of neuroimaging in the initial management of patients with minor head injury. *Ann Emerg Med* 23:1279-1283, 1994
22. Godano U, Serracchioli A, Servadei F, et al: Intracranial lesions of surgical interest in minor head injuries in paediatric patients. *Child Nerv Syst* 8:136-138, 1992
23. Greenes DS, Schutzman SA: Infants with isolated skull fracture: What are their clinical characteristics, and do they require hospitalization? *Ann Emerg Med* 30:253-259, 1997
24. Greenes DS, Schutzman SA: Occult intracranial injury in infants. *Ann Emerg Med* 32:680-686, 1998
25. Gupta SK, Reddy NM, Khosla VK, et al: Growing skull fractures: A clinical study of 41 patients. *Acta Neurochir* 139:928-932, 1997
26. Hahn YS, Raimondi AJ, McLone DG, et al: Traumatic mechanisms of head injury in child abuse. *Childs Brain* 10:229-241, 1983
27. Hahn YS, McLone DG: Risk factors in the outcome of children with minor head injury. *Pediatr Neurosurg* 19:135-142, 1993
28. Harwood-Nash DC, Hendrick EB, Hudson AR: The significance of skull fractures in children: A study of 1,187 patients. *Radiology* 101:151-155, 1971
29. Hennes H, Lee M, Smith D, et al: Clinical predictors of severe head trauma in children. *Am J Dis Child* 142:1045-1047, 1988
30. Humphreys RP, Hendrick EB, Hoffman HJ: The head-injured child who "talks and dies." *Child Nerv Syst* 6:139-142, 1990
31. Jennett B: Epidemiology of head injury. *J Neurol Neurosurg Psychiatry* 60:362-369, 1996
32. Kempe CH, Silverman FN, Steele BF, et al: The battered-child syndrome. *JAMA* 181:17-24, 1962
33. Kleinman PK, Spevak MR: Soft tissue swelling and acute skull fractures. *J Pediatr* 121:737-739, 1992
34. Kraus JF, Fife D, Cox P, et al: Incidence, severity, and external causes of pediatric brain injury. *Am J Dis Child* 140:687-693, 1986
35. Kraus JF, Rock A, Hemyari P: Brain injuries among infants, children, adolescents, and young adults. *Am J Dis Child* 144:684-691, 1990
36. Leonidas JC, Ting W, Binkiewicz A, et al: Mild head trauma in children: When is a roentgenogram necessary? *Pediatrics* 69:139-143, 1982
37. Levin HS, Mattis S, Ruff RM, et al: Neurobehavioral outcome following minor head injury: A three-center study. *J Neurosurg* 66:234-243, 1987
38. Lloyd DA, Carty H, Patterson M, et al: Predictive value of skull radiography for intracranial injury in children with blunt head injury. *Lancet* 349:821-824, 1997
39. Masters SJ: Evaluation of head trauma: Efficacy of skull films. *AJR Am J Roentgenol* 135:539-547, 1980
40. Masters SJ, McClean PM, Arcarese JS, et al: Skull x-ray examinations after head trauma: Recommendations by a multidisciplinary panel and validation study. *N Engl J Med* 316:84-91, 1987
41. Mittl RL, Grossman RI, Hiehle J, et al: Prevalence of MR evidence of diffuse axonal injury in patients with mild head injury and normal head CT findings. *AJNR Am J Neuroradiol* 15:1583-1589, 1994
42. Moreea S, Jones S, Zoltie N: Radiography for head trauma in children: What guidelines should we use? *J Accid Emerg Med* 14:13-15, 1997
43. Pietrzak M, Jagoda A, Brown L: Evaluation of minor head trauma in children younger than two years. *Am J Emerg Med* 9:153-156, 1991
44. Quayle KS, Jaffe DM, Kuppermann N, et al: Diagnostic testing for acute head injury in children: When are head computed tomography and skull radiographs indicated? *Pediatrics* [Online] 99:11, 1997. Available: <http://www.pediatrics.org/cgi/content/full/99/5/ell>
45. Ramundo ML, McKnight T, Kempf J, et al: Clinical predictors of computed tomo-

- graphic abnormalities following pediatric traumatic brain injury. *Pediatr Emerg Care* 11:1-4, 1995
46. Rivara F, Tanaguchi D, Parish RA, et al: Poor prediction of positive computed tomographic scans by clinical criteria in symptomatic pediatric head trauma. *Pediatrics* 80:579-584, 1987
 47. Rivara FP, Calonge N, Thompson RS: Population-based study of unintentional injury incidence and impact during childhood. *Am J Public Health* 79:990-994, 1989
 48. Roberts F, Shopfner CE: Plain skull roentgenograms in children with head trauma. *American Journal of Roentgenology Radium Therapy and Nuclear Medicine* 114:230-240, 1972
 49. Roddy SP, Cohn SM, Moller BA, et al: Minimal head trauma in children revisited: Is routine hospitalization required? *Pediatrics* 101:575-577, 1998
 50. Ros SP, Ros MA: Should patients with normal cranial CT scans following minor head injury be hospitalized for observation? *Pediatr Emerg Care* 5:216-217, 1989
 51. Ros SP, Cetta F: Are skull radiographs useful in the evaluation of asymptomatic infants following minor head injury? *Pediatr Emerg Care* 8:328-330, 1992
 52. Rosenthal BW, Bergman I: Intracranial injury after moderate head trauma in children. *J Pediatr* 115:346-350, 1989
 53. Sainsbury CPQ, Sibert JR: How long do we need to observe head injuries in hospital? *Arch Dis Child* 59:856-859, 1984
 54. Schunk JE, Rodgers JD, Woodward GA: The utility of head computed tomographic scanning in pediatric patients with normal neurologic examination in the emergency department. *Pediatr Emerg Care* 12:160-165, 1996
 55. Schutzman SA, Barnes PD, Mantello M, et al: Epidural hematomas in children. *Ann Emerg Med* 22:535-541, 1993
 56. Shackford SR, Wald SL, Ross SE, et al: The clinical utility of computed tomographic scanning and neurologic examination in the management of patients with minor head injuries. *J Trauma* 33:385-394, 1992
 57. Shane SA, Fuchs SM: Skull fractures in infants and predictors of associated intracranial injury. *Pediatr Emerg Care* 13:198-203, 1997
 58. Shugerman RP, Paez A, Grossman DC, et al: Epidural hemorrhage: Is it abuse? *Pediatrics* 97:664-668, 1996
 59. Snoek JW, Minderhoud JM, Wilmink JT: Delayed deterioration following mild head injury in children. *Brain* 107:15-36, 1984
 60. Sosin DM, Sniezek JE, Thurman DJ: Incidence of mild and moderate brain injury in the United States, 1991. *Brain Inj* 10:47-54, 1996
 61. Stein SC, Ross SE: Mild head injury: A plea for routine early CT scanning. *J Trauma* 33:11-13, 1992
 62. Teasdale GM, Murray G, Anderson E, et al: Risks of acute traumatic intracranial haematoma in children and adults: Implications for managing head injuries. *BMJ* 300:363-367, 1990
 63. Wilkins B: Head injury: Abuse or accident? *Arch Dis Child* 76:393-396, 1997
 64. Zimmerman RA, Bilaniuk LT, Gennarelli TA, et al: Cranial computed tomography in diagnosis and management of acute head trauma. *Am J Roentgenol* 131:27-34, 1978
 65. Zimmerman RA, Bilaniuk LT: Computed tomography in pediatric head trauma. *J Neuroradiology* 8:257-271, 1981
 66. Zuckerman GB, Conway EE: Accidental head injury. *Pediatr Ann* 26:621-632, 1997

Address reprint requests to

Kimberly S. Quayle, MD
 Division of Emergency Medicine
 St. Louis Children's Hospital
 1 Children's Place
 St. Louis, MO 63110

e-mail: quayle@a1.kids.wustl.edu