

# PEDIATRICS®

OFFICIAL JOURNAL OF THE AMERICAN ACADEMY OF PEDIATRICS

**Yield of Chest Radiography After Removal of Esophageal Foreign Bodies**  
Jeremy Fisher, Rohit Mittal, Sarah Hill, Mark L. Wulkan and Matthew S. Clifton  
*Pediatrics* 2013;131:e1497; originally published online April 22, 2013;  
DOI: 10.1542/peds.2012-3676

The online version of this article, along with updated information and services, is  
located on the World Wide Web at:

<http://pediatrics.aappublications.org/content/131/5/e1497.full.html>

PEDIATRICS is the official journal of the American Academy of Pediatrics. A monthly publication, it has been published continuously since 1948. PEDIATRICS is owned, published, and trademarked by the American Academy of Pediatrics, 141 Northwest Point Boulevard, Elk Grove Village, Illinois, 60007. Copyright © 2013 by the American Academy of Pediatrics. All rights reserved. Print ISSN: 0031-4005. Online ISSN: 1098-4275.

American Academy of Pediatrics

DEDICATED TO THE HEALTH OF ALL CHILDREN™



# Yield of Chest Radiography After Removal of Esophageal Foreign Bodies

**AUTHORS:** Jeremy Fisher, MD,<sup>a</sup> Rohit Mittal, MD,<sup>a</sup> Sarah Hill, MD,<sup>a</sup> Mark L. Wulkan, MD,<sup>b</sup> and Matthew S. Clifton, MD<sup>b</sup>

<sup>a</sup>Department of Surgery, and <sup>b</sup>Division of Pediatric Surgery, Department of Surgery, Emory University School of Medicine/Children's Healthcare of Atlanta, Egleston, Atlanta, Georgia

## KEY WORDS

esophageal foreign body, rigid esophagoscopy, postoperative chest radiography, cost containment

Dr Fisher participated in the initial study design, planned the data collection instruments, provided analysis, drafted the initial manuscript, and revised the final manuscript as submitted; Dr Mittal performed chart review and collaborated on data analysis as well as in drafting the initial manuscript; Dr Hill performed chart review, statistical analysis, and was instrumental in manuscript revisions; Dr Wulkan designed the initial study, collaborated on analysis, directed the discussion section of the manuscript, revised the manuscript, and, in partnership with Dr Clifton, had final approval of the documents as submitted; and Dr Clifton designed the study and planned the data collection instruments along with Dr Fisher. As the principal investigator, the entire study was performed under his supervision with continued analysis of data and refinement of the study. He revised the manuscript, provided critical analysis, and had final approval over the finished manuscript.

[www.pediatrics.org/cgi/doi/10.1542/peds.2012-3676](http://www.pediatrics.org/cgi/doi/10.1542/peds.2012-3676)

doi:10.1542/peds.2012-3676

Accepted for publication Jan 30, 2013

Address correspondence to Matthew Clifton, MD, Children's Healthcare of Atlanta/Emory University School of Medicine, 1405 Clifton Road NE, Atlanta, GA 30322. E-mail: [mclifto@emory.edu](mailto:mclifto@emory.edu)

PEDIATRICS (ISSN Numbers: Print, 0031-4005; Online, 1098-4275).

Copyright © 2013 by the American Academy of Pediatrics

**FINANCIAL DISCLOSURE:** *The authors have indicated they have no financial relationships relevant to this article to disclose.*

**FUNDING:** No external funding.



**WHAT'S KNOWN ON THIS SUBJECT:** Perforation in the setting of retained esophageal foreign body is rare, but can be catastrophic. The role of imaging in screening for injury after removal has not previously been studied.



**WHAT THIS STUDY ADDS:** The rate of esophageal injury among children with retained esophageal foreign body is 1.3%. Intraoperative findings suggestive of injury are predictive of perforation. Routine chest radiography is not warranted in those who do not meet this criterion.

## abstract

**OBJECTIVES:** The aim of this study was to determine the benefit of routine postoperative chest radiography after removal of esophageal foreign bodies in children.

**METHODS:** Medical records were reviewed of all patients evaluated with an esophageal foreign body at a single children's hospital over 10 years. Operative records and imaging reports were reviewed for evidence of esophageal injury.

**RESULTS:** Of 803 records identified, 690 were included. All underwent rigid esophagoscopy and foreign body removal. The most common items removed were coins (94%), food boluses (3%), and batteries (2%). The rate of esophageal injury was 1.3% (9 patients). No injuries were identified on chest radiographs done as routine or for concern of injury. Patients with operative findings suggestive of an esophageal injury ( $n = 105$ ) were significantly more likely to have an injury (8.6% vs 0%,  $P = .0001$ ). Of the 585 children who did not have physical evidence of injury, 40% ( $n = 235$ ) received a routine chest radiograph. Regardless of the indication, no injuries were identified on chest films.

**CONCLUSIONS:** We conclude that intraoperative findings during rigid esophagoscopy suggestive of an injury are predictive of esophageal perforation. Routine chest radiography is not warranted in children who do not meet this criterion. In patients with a concern for injury, we suggest that chest radiography should be deferred in favor of esophagram. *Pediatrics* 2013;131:e1497–e1501

Ingestion of foreign bodies is a common problem in children. The 116 000 to 180 000 cases reported to US poison control centers per year likely represent a fraction of actual cases.<sup>1,2</sup> Although most of these foreign bodies pass uneventfully, the ones that do not tend to remain in the narrowest locations along the gastrointestinal tract, notably in the esophagus at the level of the cricopharyngeus.<sup>3,4</sup> The most common presenting symptoms are pain, dysphagia, drooling, and vomiting,<sup>3</sup> although nearly half of the patients may be asymptomatic.<sup>5</sup> Pediatric surgeons frequently evaluate patients with retained esophageal foreign bodies. Although most do not result in significant complications,<sup>6</sup> strictures can occur and catastrophic outcomes have been described.<sup>7-9</sup> For this reason, removal is indicated, although some authors have recommended a trial of passage in asymptomatic patients.<sup>10,11</sup>

Multiple techniques have been described for clearing esophageal foreign bodies, including balloon extraction, bougienage, and flexible or rigid esophagoscopy.<sup>12-18</sup> Rigid esophagoscopy is a well-established, safe, and highly effective technique that offers multiple advantages, including the ability to directly visualize the esophageal mucosa.<sup>19,20</sup> Additionally, a variety of forceps are available for use based on the size and shape of the object. This technique is specifically indicated for long indwelling objects and button batteries in which preprocedural suspicion of injury is significant. At our institution, this is the preferred technique for esophageal foreign body removal.

Generally, the object is visualized and removed by using a rigid esophagoscope. The esophagoscope is reinserted after removal of the object to evaluate for further objects and assess for injury to the tissue. Despite this second look, many surgeons elect for a plain chest radiograph in the recovery room

to evaluate for gross esophageal perforation. The utility of such studies has not previously been studied.

## METHODS

Rigid esophagoscopy and foreign body removal is performed under general anesthesia with an attending pediatric surgeon present for the procedure. After extraction of the foreign body, the esophagoscope is reintroduced to evaluate for a mucosal injury. Some attending surgeons elect for a routine postoperative chest radiograph, some do not. Although patients are not formally randomized, this pattern allows for clear retrospective analysis of the utility of such studies.

Over the 10-year period from May 2000 to December 2010, 803 children presented for surgical consultation from the emergency department at Children's Healthcare of Atlanta, Egleston, for a foreign body retained in the esophagus. The procedures analyzed were distributed among 8 pediatric surgeons. After institutional review board approval, the authors reviewed the medical records of this retrospective cohort, including clinical notes, imaging reports, and operative reports. Those who reviewed the records were trained in the use of the electronic medical record software and were well accustomed to its clinical use. Two reviewers redundantly examined the records of those with positive operative findings. To limit the scope of the study to the most common patient scenario, patients with any previous chest or foregut surgery or congenital anatomic abnormality (such as esophageal atresias, strictures, or large-vessel anomalies) were excluded. All patients included underwent rigid esophagoscopy and foreign body removal.

Operative findings were reviewed, specifically noting those findings that were concerning for esophageal injury (ie, mucosal burn, extensive erosion/exudate, bleeding) and the objects removed were noted. Whether postoperative imaging

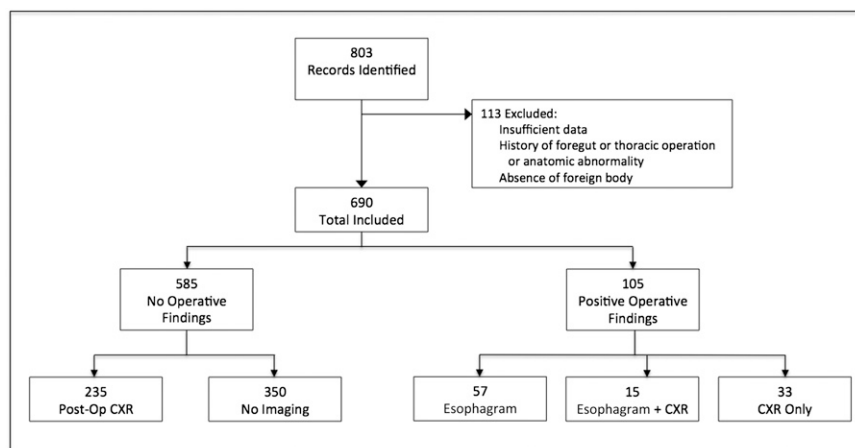
was performed and the modalities were recorded. Final imaging reports read by attending pediatric radiologists were evaluated for suggestion of esophageal injury. Specifically, mention of pneumothorax, effusion, or pneumomediastinum on plain film of the chest was recorded. Esophagrams were performed with oral water-soluble contrast, followed by oral barium if no extravasation was seen. Patient position was generally not listed. For esophagrams, radiologist reports containing terms such as "mucosal tear," "submucosal leak," "traumatic diverticulum," or "extravasation of contrast" were recorded.

## RESULTS

Over the study period, 803 records were identified, of which 690 met inclusion criteria (Fig 1). The mean age at presentation was 3.5 years (range: 3 months to 17 years); 51% were boys. The most commonly identified items were coins (94%), food boluses (3%), and batteries (2%). A total of at least \$34.30 in coins was removed from esophagi. From our cohort, all objects were successfully removed by rigid esophagoscopy during a single procedure (100% success rate).

Of the 585 children who did not have esophagoscopy evidence of injury, 40% ( $n = 235$ ) received a routine chest radiograph. No injuries were identified on chest films done as routine or for concern for injury.

The overall rate of radiographically confirmed esophageal injury was 1.3% (9 patients). No injuries were identified on chest films done as routine or for concern of injury. Patients with operative findings concerning for an esophageal injury ( $n = 105$ ) were significantly more likely to have an injury confirmed on esophagram (8.5% vs 0%,  $P = .0001$ ). Of those patients with positive findings on esophagram, only 2 also received a postoperative chest plain film. Both



**FIGURE 1**  
Flowchart for study exclusion and included patient groups.

of these failed to demonstrate pneumomediastinum, pneumothorax, or pleural effusion.

Of the 9 patients with positive esophagrams, 3 had clear symptoms related to their injuries. Five of these patients underwent nasogastric or nasojejunal tube placement with or without parenteral nutrition and antibiotics, which may have preempted or prevented the development of symptoms. One was admitted and observed without further therapy.

The objects retrieved from those patients with esophageal injury included 4 coins, 3 batteries, 1 metallic object (spring), and 1 plastic suction cup that was indwelling for more than a year (Table 1).

## DISCUSSION

In this era when cost containment has become an essential element of patient care, treatment algorithms must be not only effective, but also fiscally responsible. The utility of each imaging study must be carefully weighed.<sup>21</sup> At \$305 per plain chest film, charges for chest radiographs amounted to \$86 315 over the study period (235 routine, 283 total). Other cost-cutting measures in treating esophageal foreign bodies have been addressed, for example alternative methods of extraction and the

necessity of preoperative imaging.<sup>3,12–17</sup> Additionally, the harmful effects of ionizing radiation (with respect to future risk for malignancy) are a recognized source of long-term morbidity to children. Although the dose of radiation resulting from a chest radiograph is small, it should still be eliminated if exposure is unnecessary. To our knowledge, the utility of postoperative imaging after esophagoscopy has not been examined.

Perforation from esophageal foreign bodies is uncommon in children. The described complications include mediastinitis with or without abscess,<sup>6,22</sup> esophageal-airway fistulas,<sup>23,24</sup> esophageal-vascular fistulas<sup>6,22,25</sup> extraluminal migration of object,<sup>24,26–29</sup> and false diverticula.<sup>28</sup> In the available literature from the 1970s to the present, most studies demonstrated an injury rate of about 1%, with 1 review reporting 0.1%<sup>18</sup> and several smaller studies as high as 4% to 6%.<sup>30–33</sup> The largest series of children previously recorded in the literature examined 500 patients undergoing foreign body extraction, but did not quote a complication rate.<sup>16</sup> Nandi and Ong<sup>6</sup> published a series of 2394 patients with esophageal foreign bodies, of which 343 were children. Their group quotes an overall esophageal perforation rate of 0.91%, but only

a 0.3% rate in children (1 injury). Our rate of 1.3% reinforces the bulk of the modern literature.

Our data suggest that a high clinical suspicion for injury based on history and observation at esophagoscopy predicts esophageal injury by esophagram (8.5% vs 0% without suspicion,  $P < .001$ ). The operative findings present in those with injury (as defined by positive esophagram) included mucosal burns (batteries), extensive erosion of the object (coins), significant exudate, or bleeding. Of the patients who lacked these findings, there were no injuries seen on radiographic evaluation and no missed injuries.

As a test for injury, absence of significant findings on esophagram strongly predicts the absence of true injury (negative predictive value 100%). It is only moderately specific (86%). However, if the goal of the surgeon is to rule out injury, these data strongly support using the test in this manner.

Although our study is not powered to quantify sensitivity for chest radiography for esophageal injury, the absence of positive findings on any chest plain film reviewed (including those performed on patients with an esophagram demonstrating injury) suggests that postoperative chest radiography is not of particular value in diagnosing esophageal injury after rigid esophagoscopy with removal of a foreign body (sensitivity 0%). We propose that contrast esophagram should be the preferred study for those patients with worrisome findings on esophagoscopy.

As would logically follow, sharp or irregular objects and button batteries may be more likely to cause injury.<sup>10</sup> Although 1 metal spring caused an injury, sharp or irregular objects were not strongly associated with injuries in this cohort. Although batteries represented only 2% of the objects removed in this study, they resulted in 30% of the injuries. These data underscore the

**TABLE 1** Summary of Patients With Esophageal Injuries

	Age, mo	Object	Duration Indwelling, If Known	Operative Findings	Clinical Symptoms of Injury?	Radiographic Study	Injury
1	38	Suction cup (plastic)	>1 y	Mediastinal abscess, broncho-esophageal fistula	Cough, emesis, dyspnea, dysphagia	CXR CT	Negative Mediastinal abscess, broncho-esophageal fistula
2	12	Metal spring	2 wk	Bleeding, exudate, inflammation, difficult to remove	Respiratory failure	CXR Esophagram	Negative Traumatic diverticulum
3	12	Battery	15 h	Black and white eschar, (third-degree burn)	None	Esophagram	Contained submucosal leak (pseudodiverticulum)
4	26	Coin	—	Badly corroded coin, mucosal erosion and bleeding	None	Esophagram	Contained extravasation and stricture
5	10	Coin	—	Deep ulceration / fissure	None	Esophagram	Contained submucosal -leak
6	9	Coin	—	Copious exudate	None	Esophagram	Contained extravasation
7	29	Coin	—	Severe corrosion	None	Esophagram	Pseudodiverticulum
8	24	Battery	4 d	Large mucosal burn (2 cm × 50% circumference)	None	Esophagram	Contained extravasation
9	11	Battery	6 h	Mucosal erosion, "chocolate" exudate	Fever, dyspnea, respiratory failure	CXR Esophagram CT, endoscopy	Negative Narrowing Tracheoesophageal fistula

CT, computed tomography; CXR, chest x-ray; — indicates an unknown duration of indwelling time.

need for a high index of suspicion for injury in those patients who have potentially ingested button batteries.

The practice variation within our surgical division falls into 1 of 2 cohorts: those who order a routine post-operative chest radiograph and those who do not. Whether a "routine" film was performed depended entirely on surgeon preference. Recognizing the limits of a retrospective study, this de facto randomization lends itself well to analysis. In those patients who did not have findings suggestive of injury on esophagoscopy, there was a fairly even demographic distribution between

those receiving chest radiographs and those with no imaging (mean age 3.5 years versus 3.4, 116 [49%] male versus 182 [52%], respectively).

Our inclusion criteria were designed to focus on the most common presentation of this problem. Because we excluded those with previous chest and foregut surgery, these recommendations cannot be clearly applied to those patients. Last, the study is limited by lack of dedicated follow-up. In our city, our affiliated hospitals take the vast majority of pediatric visits. These share a single electronic medical record, which allows us to retrospectively determine that none of our

patients returned with clinical symptoms of missed injury. Because there was no dedicated follow-up, however, it is impossible to truly determine if there were any missed injuries.

## CONCLUSIONS

Positive findings on esophagoscopy predict esophageal injury. Routine evaluation with chest radiography after rigid esophagoscopy for foreign body removal is not warranted and not cost effective. In patients with evidence of injury during esophagoscopy, we suggest that chest radiography should be deferred in favor of a contrast esophagram.

## REFERENCES

- Bronstein AC, Spyker DA, Cantilena LR Jr, Green JL, Rumack BH, Dart RC. 2010 Annual Report of the American Association of Poison Control Centers' National Poison Data System (NPDS): 28th Annual Report. *Clin Toxicol (Phila)*. 2011;49(10):910–941
- Litovitz TL, Klein-Schwartz W, White S, et al. 1999 annual report of the American Association of Poison Control Centers Toxic Exposure Surveillance System. *Am J Emerg Med*. 2000;18(5):517–574
- Rybojad B, Niedzielska G, Niedzielski A, Rudnicka-Drozak E, Rybojad P. Esophageal foreign bodies in pediatric patients: a thirteen-year retrospective study. *ScientificWorldJournal*. 2012;2012:102642
- Stack LB, Munter DW. Foreign bodies in the gastrointestinal tract. *Emerg Med Clin North Am*. 1996;14(3):493–521
- Arana A, Hauser B, Hachimi-Idrissi S, Vandenplas Y. Management of ingested foreign bodies in childhood and review of the literature. *Eur J Pediatr*. 2001;160(8):468–472
- Nandi P, Ong GB. Foreign body in the oesophagus: review of 2394 cases. *Br J Surg*. 1978;65(1):5–9
- Hill SJ, Zarroug AE, Ricketts RR, Veeraswamy R. Bedside placement of an aortic occlusion balloon to control a ruptured aorto-esophageal fistula in a small child. *Ann Vasc Surg*. 2010;24(6):822.e7–9
- Jiraki K. Aortoesophageal conduit due to a foreign body. *Am J Forensic Med Pathol*. 1996;17(4):347–348



9. Tucker JG, Kim HH, Lucas GW. Esophageal perforation caused by coin ingestion. *South Med J*. 1994;87(2):269–272
10. Kay M, Wyllie R. Pediatric foreign bodies and their management. *Curr Gastroenterol Rep*. 2005;7(3):212–218
11. Waltzman ML. Management of esophageal coins. *Curr Opin Pediatr*. 2006;18(5):571–574
12. Bonadio WA, Jona JZ, Glicklich M, Cohen R. Esophageal bougienage technique for coin ingestion in children. *J Pediatr Surg*. 1988;23(10):917–918
13. Calkins CM, Christians KK, Sell LL. Cost analysis in the management of esophageal coins: endoscopy versus bougienage. *J Pediatr Surg*. 1999;34(3):412–414
14. Christie DL, Ament ME. Removal of foreign bodies from esophagus and stomach with flexible fiberoptic panendoscopes. *Pediatrics*. 1976;57(6):931–934
15. Jona JZ, Glicklich M, Cohen RD. The contraindications for blind esophageal bougienage for coin ingestion in children. *J Pediatr Surg*. 1988;23(4):328–330
16. Little DC, Shah SR, St Peter SD, et al. Esophageal foreign bodies in the pediatric population: our first 500 cases. *J Pediatr Surg*. 2006;41(5):914–918
17. Schunk JE, Harrison AM, Corneli HM, Nixon GW. Fluoroscopic Foley catheter removal of esophageal foreign bodies in children: experience with 415 episodes. *Pediatrics*. 1994;94(5):709–714
18. Conners GP. A literature-based comparison of three methods of pediatric esophageal coin removal. *Pediatr Emerg Care*. 1997;13(2):154–157
19. Chen MK, Beierle EA. Gastrointestinal foreign bodies. *Pediatr Ann*. 2001;30(12):736–742
20. Crysdale WS, Sendi KS, Yoo J. Esophageal foreign bodies in children. 15-year review of 484 cases. *Ann Otol Rhinol Laryngol*. 1991;100(4 pt 1):320–324
21. Rosenbaum L, Lamas D. Cents and sensitivity—teaching physicians to think about costs. *N Engl J Med*. 2012;367(2):99–101
22. Remsen K, Lawson W, Biller HF, Som ML. Unusual presentations of penetrating foreign bodies of the upper aerodigestive tract. *Ann Otol Rhinol Laryngol Suppl*. 1983;105:32–44
23. Newman DE. The radiolucent esophageal foreign body: an often-forgotten cause of respiratory symptoms. *J Pediatr*. 1978;92(1):60–63
24. Yee KF, Schild JA, Holinger PH. Extraluminal foreign bodies (coins) in the food and air passages. *Ann Otol Rhinol Laryngol*. 1975;84(5 pt 1):619–623
25. Macpherson RI, Hill JG, Othersen HB, Tagge EP, Smith CD. Esophageal foreign bodies in children: diagnosis, treatment, and complications. *AJR Am J Roentgenol*. 1996;166(4):919–924
26. Burton DM, Stith JA. Extraluminal esophageal coin erosion in children. Case report and review. *Int J Pediatr Otorhinolaryngol*. 1992;23(2):187–194
27. Janik JS, Bailey WC, Burrington JD. Occult coin perforation of the esophagus. *J Pediatr Surg*. 1986;21(9):794–797
28. Katz KR, Emmens RW, Wood BP. Radiological case of the month. Esophageal obstruction and abscess formation secondary to impacted, eroding tiddlywink. *Am J Dis Child*. 1989;143(8):961–962
29. Nahman BJ, Mueller CF. Asymptomatic esophageal perforation by a coin in a child. *Ann Emerg Med*. 1984;13(8):627–629
30. Ament ME, Christie DL. Upper gastrointestinal fiberoptic endoscopy in pediatric patients. *Gastroenterology*. 1977;72(6):1244–1248
31. Brady PG, Johnson WF. Removal of foreign bodies: the flexible fiberoptic endoscope. *South Med J*. 1977;70(6):702–704
32. Tedesco FJ. Endoscopic removal of foreign bodies using fiberoptic instruments. *South Med J*. 1977;70(8):991–992, 994
33. Vizcarrondo FJ, Brady PG, Nord HJ. Foreign bodies of the upper gastrointestinal tract. *Gastrointest Endosc*. 1983;29(3):208–210

**Yield of Chest Radiography After Removal of Esophageal Foreign Bodies**  
Jeremy Fisher, Rohit Mittal, Sarah Hill, Mark L. Wulkan and Matthew S. Clifton  
*Pediatrics* 2013;131:e1497; originally published online April 22, 2013;  
DOI: 10.1542/peds.2012-3676

<b>Updated Information &amp; Services</b>	including high resolution figures, can be found at: <a href="http://pediatrics.aappublications.org/content/131/5/e1497.full.html">http://pediatrics.aappublications.org/content/131/5/e1497.full.html</a>
<b>References</b>	This article cites 31 articles, 2 of which can be accessed free at: <a href="http://pediatrics.aappublications.org/content/131/5/e1497.full.html#ref-list-1">http://pediatrics.aappublications.org/content/131/5/e1497.full.html#ref-list-1</a>
<b>Subspecialty Collections</b>	This article, along with others on similar topics, appears in the following collection(s): <b>Surgery</b> <a href="http://pediatrics.aappublications.org/cgi/collection/surgery">http://pediatrics.aappublications.org/cgi/collection/surgery</a>
<b>Permissions &amp; Licensing</b>	Information about reproducing this article in parts (figures, tables) or in its entirety can be found online at: <a href="http://pediatrics.aappublications.org/site/misc/Permissions.xhtml">http://pediatrics.aappublications.org/site/misc/Permissions.xhtml</a>
<b>Reprints</b>	Information about ordering reprints can be found online: <a href="http://pediatrics.aappublications.org/site/misc/reprints.xhtml">http://pediatrics.aappublications.org/site/misc/reprints.xhtml</a>

PEDIATRICS is the official journal of the American Academy of Pediatrics. A monthly publication, it has been published continuously since 1948. PEDIATRICS is owned, published, and trademarked by the American Academy of Pediatrics, 141 Northwest Point Boulevard, Elk Grove Village, Illinois, 60007. Copyright © 2013 by the American Academy of Pediatrics. All rights reserved. Print ISSN: 0031-4005. Online ISSN: 1098-4275.

American Academy of Pediatrics

DEDICATED TO THE HEALTH OF ALL CHILDREN™

