

PEDIATRICS®

OFFICIAL JOURNAL OF THE AMERICAN ACADEMY OF PEDIATRICS

Asymptomatic Inflammatory Bowel Disease Presenting With Mucocutaneous Findings

Sheila S. Galbraith, Beth A. Drolet, Subra Kugathasan, Amy S. Paller and Nancy B. Esterly

Pediatrics 2005;116:e439; originally published online August 11, 2005;
DOI: 10.1542/peds.2004-2281

The online version of this article, along with updated information and services, is located on the World Wide Web at:

<http://pediatrics.aappublications.org/content/116/3/e439.full.html>

PEDIATRICS is the official journal of the American Academy of Pediatrics. A monthly publication, it has been published continuously since 1948. PEDIATRICS is owned, published, and trademarked by the American Academy of Pediatrics, 141 Northwest Point Boulevard, Elk Grove Village, Illinois, 60007. Copyright © 2005 by the American Academy of Pediatrics. All rights reserved. Print ISSN: 0031-4005. Online ISSN: 1098-4275.

American Academy of Pediatrics

DEDICATED TO THE HEALTH OF ALL CHILDREN™



Asymptomatic Inflammatory Bowel Disease Presenting With Mucocutaneous Findings

Sheila S. Galbraith, MD*; Beth A. Drolet, MD*; Subra Kugathasan, MD‡; Amy S. Paller, MD§; and Nancy B. Esterly, MD*

ABSTRACT. Although inflammatory bowel disease (IBD) typically presents with gastrointestinal complaints, mucocutaneous lesions are commonly associated and can precede gastrointestinal symptoms, thereby alerting the clinician to the diagnosis of IBD before the onset of gastrointestinal symptoms. Nine children are reported who had no gastrointestinal symptoms suggestive of IBD but presented with mucocutaneous findings of IBD and were subsequently diagnosed with Crohn's disease or ulcerative colitis based on characteristic features on gastrointestinal endoscopy and/or biopsies. The majority of the patients had oral and perianal lesions. We believe that IBD is a common etiology for persistent oral lesions in the pediatric population. In addition to a good history, children with unexplained oral mucous membrane lesions should have an examination of the rectal and genital mucosa as well as tests for complete blood count, iron levels, sedimentation rate, albumin, and occult blood in the stool with endoscopy and biopsies to rule out IBD if indicated. *Pediatrics* 2005;116:e439–e444. URL: www.pediatrics.org/cgi/doi/10.1542/peds.2004-2281; *Crohn's disease, cutaneous, inflammatory bowel disease, oral, pediatrics*.

ABBREVIATIONS. IBD, inflammatory bowel disease; 6-MP, 6-mercaptopurine; ESR, erythrocyte sedimentation rate.

Inflammatory bowel disease (IBD) is a group of gastrointestinal disorders characterized by relapsing and remitting signs and symptoms. Intestinal manifestations such as abdominal pain, diarrhea, fever, weight loss, and extraintestinal manifestations including mucocutaneous lesions, iritis, and arthritis may be associated with IBD. Mucocutaneous lesions are relatively common during the course of IBD. Less commonly, however, they can be a presenting finding, thereby alerting the clinician to the diagnosis of IBD before the onset of gastrointestinal symptoms. We describe 9 children from 2 medical institutions in whom mucocutaneous lesions pre-

ceded abdominal manifestations and led to an early diagnosis of IBD.

REPRESENTATIVE CASES

Patient 1

A 6-year-old white boy presented with a 5-month history of intermittent upper-lip swelling associated with eczematous skin changes and gingival edema (Fig 1). Over the subsequent 3 years, he developed worsening of the upper-lip swelling as well as angular cheilitis and lower-lip involvement (Fig 2). He denied any systemic symptoms including facial paralysis, abdominal pain, and diarrhea. A biopsy specimen from the oral mucosa showed a hyperplastic mucosa with spongiosis and a dense lymphocytic infiltrate with small granulomas in the submucosa. Patch tests, complete blood count, tuberculosis skin tests, chest radiograph, and pulmonary function tests were within normal limits.

A repeat biopsy was planned because of lack of improvement with several therapies including topical steroids, antihistamines, amoxicillin-clavulanate, and minocycline for presumed Melkersson-Rosenthal syndrome. On returning to the clinic for biopsy, his mother mentioned a perianal pustule that had been present for some time. Given this new information, the oral biopsy was not performed; he instead was referred to a gastroenterologist. The patient was found to have microcytic anemia (hemoglobin: 11.1 g/dL; mean corpuscular volume: 75 fL) and hypoalbuminemia (3.3 g/dL) at that time. Esophagogastroduodenoscopy was unremarkable; however, patchy erythema, erosions, and pseudopolyps were seen during colonoscopy. Biopsies from the colon showed

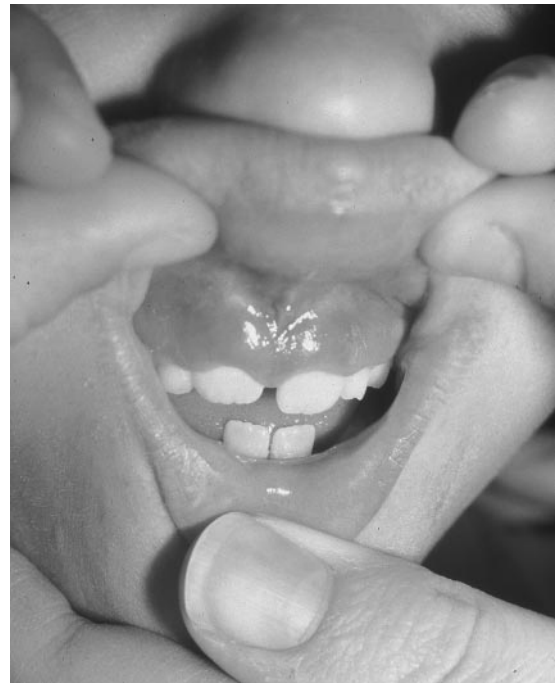


Fig 1. Patient 1: upper-lip swelling and gingival edema.

From the *Department of Dermatology and Pediatrics, Medical College of Wisconsin, Milwaukee, Wisconsin; †Department of Gastroenterology and Pediatrics, Medical College of Wisconsin, Milwaukee, Wisconsin; and ‡Department of Dermatology and Pediatrics, Feinberg School of Medicine, Northwestern University, Chicago, Illinois.

Accepted for publication Mar 31, 2005.

doi:10.1542/peds.2004-2281

No conflict of interest declared.

Address correspondence to Sheila S. Galbraith, MD, Department of Dermatology, Medical College of Wisconsin, 9200 W Wisconsin Ave, Milwaukee, WI 53226. E-mail: sgalbrai@mcw.edu

PEDIATRICS (ISSN 0031 4005). Copyright © 2005 by the American Academy of Pediatrics.

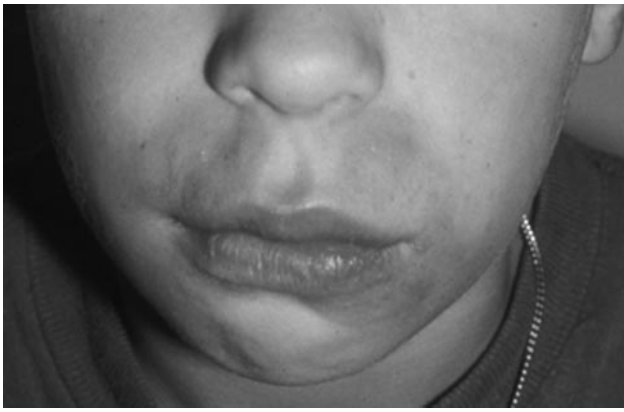

Fig 2. Patient 1: upper- and lower-lip swelling 3 years later.

gastritis, terminal ileum granulomas, and granulomatous colitis, confirming the diagnosis of Crohn's disease.

The perianal lesion proved to be a fistula, and 6-mercaptopurine (6-MP) was started. Metronidazole was added intermittently to treat the fistula further. There was mild improvement of the granulomatous cheilitis; however, the fistula remained patent. Infliximab was started, with complete resolution of the oral lesions, closure of the fistula, and normalization of laboratory abnormalities after 3 infusions. He is in clinical and biochemical remission without intestinal or extraintestinal manifestations while maintained on scheduled 8- to 10-week-interval infliximab therapy.

Patient 2

An 8-year-old white boy had a 2-year history of recurrent oral ulcerations with hyperplastic ridges in the inferior gingival sulcus bilaterally (Fig 3). He denied any gastrointestinal symptoms. A previous oral biopsy was reviewed and showed a small granuloma in the submucosa. He also had a history of perianal skin tags and fissures. Gastrointestinal evaluation revealed esophagitis, gastritis, and multiple aphthous ulcers in the sigmoid colon. Biopsy specimens showed esophagitis with granulomas and granulomatous colitis consistent with Crohn's disease. Work-up subsequently revealed hypoalbuminemia (3.2 g/dL) and an elevated erythrocyte sedimentation rate (ESR) (32 mm/hour). Monotherapy with 6-MP resulted in resolution of his oral ulcers.

Patient 3

A 12-year-old obese white boy (body mass index: 97th percentile) presented with a 6-month history of an erythematous plaque on his right lower extremity that more recently had become warm to the touch, tender, and ulcerated with indurated violaceous borders (Fig 4). The patient denied any trauma to the area. Two biopsies performed elsewhere were consistent with folliculitis, and the patient had been treated with Augmentin and topical antibiotics with no improvement. Repeat biopsy showed suppurative folliculitis which, along with the typical clinical presentation, was consistent with pyoderma gangrenosum. Fungal culture and acid-fast bacillus stains were negative. His ESR was slightly elevated (14 mm/hour). The patient denied any gastrointestinal complaints, but upper and lower endoscopy showed multiple ulcerations in the gastric antrum and ileum. Biopsy specimens showed gastritis, ileitis, and crypt destruction with giant-cell reaction in the colon consistent with Crohn's disease. He initially received intralesional corticosteroids for the pyoderma gangrenosum; however, after the diagnosis of Crohn's disease was made,

TABLE 1. Case Presentations

Patient	Gender	Age, y	Presentation	Perianal Lesions	Mucosal/Cutaneous Biopsy	Endoscopic Findings
1*	Male	6	Upper-lip swelling; gingival edema; eczematous patches	Perianal pustule (fistula)	Dense lymphocytic infiltrate and small granulomas in the submucosa of oral mucosa	EGD normal; erythema, erosions, and pseudopolyps in colon
2	Male	8	Oral ulcers with hyperplastic ridges	Perianal skin tags and fissures	Small submucosal granuloma of oral mucosa	Multiple ulcers in the sigmoid colon
3	Male	12	Pyoderma gangrenosum, right pretibial; obesity	None	Suppurative folliculitis consistent with pyoderma gangrenosum	Multiple ulcers in the ileum
4	Male	5	Cutaneous pustules; oral erosions	Perianal ulcer	Pustular dermatosis of left leg and left trunk	Upper and lower endoscopies grossly normal
5†	Female	8	Right vulvar erythema and swelling	Perianal skin tags	Perirectal tag granulomas	Erosions in the rectum and sigmoid colon
6*	Male	13	Pyoderma gangrenosum, right lower extremity	None	Pyoderma gangrenosum	Ulcerations in right colon
7	Male	3	Upper-lip swelling and purple discoloration	Rectal skin tags and fissures	Granulomas of oral mucosa	Irregularities in the terminal ileum; ulcerations in the sigmoid colon
8	Male	14	Right upper-lip swelling; angular cheilitis; aphthous ulcers; obesity	Perianal fissure; inguinal fistula; gluteal abscesses; pilonidal cyst	Dense mixed inflammatory infiltrate of oral mucosa	Esophagitis; gastritis; ileitis
9	Male	4	Upper gingival edema; lip swelling	Perianal fissures	Granulomatous inflammation of oral mucosa	Upper and lower endoscopy normal

EGD indicates esophagogastroduodenoscopy; GI, gastrointestinal.

* Patients were reported previously in *J Pediatr Gastroenterol Nutr.* 2003;37:150–154.

† Patient was reported previously in *J Am Acad Dermatol.* 1992;27(5 pt 2):893–895.

Continued

infliximab and methotrexate were initiated, which led to almost complete resolution of the pyoderma gangrenosum.

RESULTS

In our series of children with silent IBD, mucocutaneous lesions appeared before gastrointestinal signs as the manifestation of Crohn's disease (8 of 9) or ulcerative colitis (1 of 9). (Table 1 provides a summary of these cases.) Of the 9 patients, 8 were male, and the mean age was 8 years. Although patients with IBD tend not to be overweight, 2 of our patients were obese (patients 3 and 8). Six children presented with oral manifestations, 1 had genital lesions, and 2 had pyoderma gangrenosum. All patients were asked about gastrointestinal symptoms, fever, weight loss, and joint pain at presentation and denied any such symptoms. The majority of our patients (7 of 9) had perianal lesions at presentation; however, several of the perianal lesions were not discovered on initial evaluation but only became apparent during subsequent examinations. The time to diagnosis of IBD after development of the mucocutaneous findings ranged from 1 month to 42 months. In general, patients with oral and perianal lesions experienced a longer time until diagnosis compared with patients with lesions that presented elsewhere. One patient (patient 8) was diagnosed with Crohn's disease on repeat endoscopy after the initial endoscopy that was performed ~1.5 years

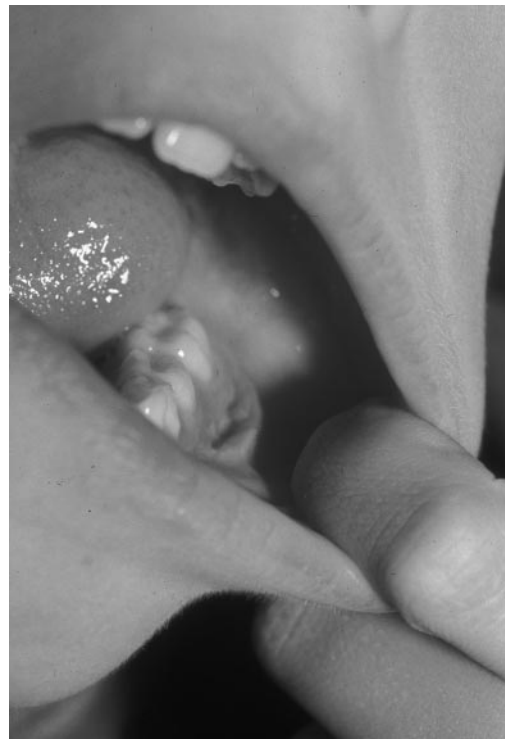

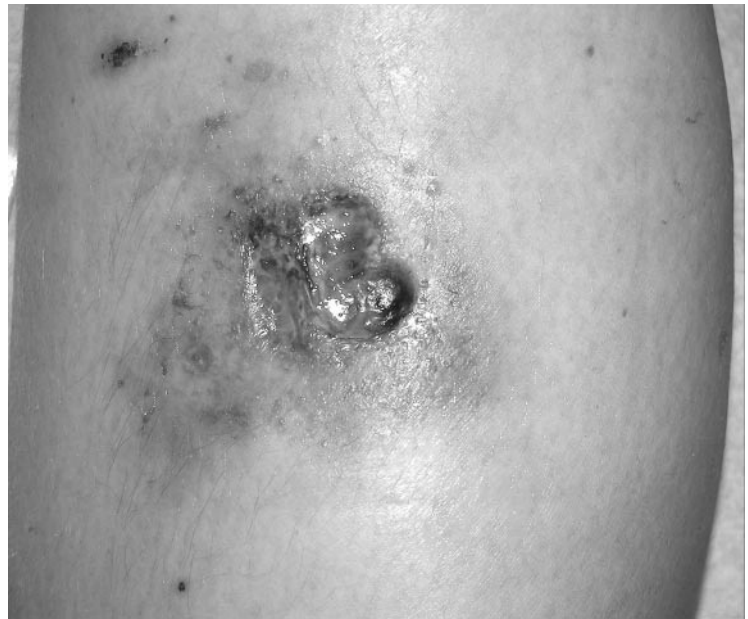Fig 3. Patient 2: linear oral ulceration and hyperplastic ridges in the inferior gingival sulcus.

TABLE 1. Case Presentations

Continued

GI Biopsy	Other Findings	Diagnosis	Time to Diagnosis, mo	Treatment	Responded to Treatment?	Development of GI Findings
Gastritis, duodenitis; granuloma in the terminal ileum; granulomatous colitis	Microcytic anemia; hypoalbuminemia	Crohn's disease	42	6-MP; metronidazole; infliximab	Yes	None
Gastritis; granulomas in esophagus; granulomatous colitis	Hypoalbuminemia; ESR = 32 mm/h	Crohn's disease	24	6-MP	Yes	None
Gastritis, ileitis, and crypt destruction with giant-cell reaction in colon	ESR = 14 mm/h	Crohn's disease	6	Intralesional steroids; infliximab; methotrexate	Yes	None
Mild colitis with cryptitis and crypt abscesses	ESR = 12 mm/h	Ulcerative colitis	1	Intravenous steroids	Yes	None
Chronic inflammation and granuloma	None	Crohn's disease	6	Sulfasalazine	Yes	Diarrhea after therapy was discontinued 17 mo later
Gastritis and chronic colitis consistent with Crohn's disease	Microcytic anemia; ESR = 26 mm/h	Crohn's disease	3	Intralesional steroids; 6-MP; infliximab	Yes	Diarrhea, abdominal pain, and bloody stools 3 y after third infliximab infusion
Granulomatous infiltrate	ESR = 45 mm/h	Crohn's disease	3	Prednisolone; metronidazole; 6-MP	Yes	One episode of bright-red blood per rectum before treatment instituted
Granulomas and focal granulomatous colitis	Microcytic anemia; hypoalbuminemia; ESR = 27 mm/h	Crohn's disease	7 (oral); 20 (perianal)	Infliximab; methotrexate	Lost to follow-up	None: lost to follow-up
Chronic colitis of cecum and ascending colon	Hypoalbuminemia	Crohn's disease	9 (oral); 18 (perianal)	Azathioprine	Medication recently instituted	None

Fig 4. Patient 3: 2 × 2-cm ulcer with indurated violaceous borders on the right lower extremity.



prior was normal. In all patients followed after instituting therapy, the mucocutaneous lesions responded to therapy for their IBD.

DISCUSSION

Although IBD typically presents with gastrointestinal complaints, mucocutaneous lesions have been reported to occur in 15% to 44% of cases and, when present, can precede gastrointestinal symptoms.^{1,2,3,4} Gregory and Ho⁵ reviewed the mucocutaneous lesions of IBD and divided them into specific, reactive, and miscellaneous categories (Table 2).

Although uncommon in children, pyoderma gangrenosum is a common mucocutaneous feature of IBD. Typically, the early papulopustules or hemorrhagic bullae rapidly enlarge, become necrotic, and ulcerate. The ulcerations have a characteristic violaceous, undermined border (Fig 4). Lesions can occur on any part of the body but are most frequently located on the lower extremities. Pyoderma gangrenosum is characterized by pathergy (predilection for lesions in areas of trauma); thus, aggressive debridement must be avoided. Twenty percent of adult patients with pyoderma gangrenosum will have associated IBD.⁶ It is associated more commonly with ulcerative colitis than Crohn's disease, occurring in 5% to 12% and 1% to 2% of patients, respectively.^{3,5,7} Pyoderma gangrenosum is uncommon in children, with 4% of cases reported in children <15 years old.⁸ Although IBD is the most common underlying cause of pyoderma gangrenosum in children, pyoderma gangrenosum in children can be associated with several other systemic disorders including immunodeficiencies (primary and HIV related), leukemia, hepatitis, and arthritis.^{9,10} The occurrence of pyoderma gangrenosum preceding gastrointestinal symptoms in IBD has only been described in a few patients.^{6,8,11}

Perianal lesions including skin tags, fistulas, fissures, and abscesses are characteristic of Crohn's disease and occur during the course of IBD in 60% to 82% of patients; however, 25% to 30% of patients

TABLE 2. Mucocutaneous Lesions Associated With IBD⁵

Specific	Perianal fissures, fistulas, and skin tags
	Oral Crohn's disease
	Metastatic Crohn's disease
Reactive	Erythema nodosum
	Pyoderma gangrenosum
	Aphthous ulcers
	Vesiculopustular eruption
	Pyoderma vegetans
	Necrotizing vasculitis
	Cutaneous polyarteritis nodosa
	Erythema multiforme
	Urticaria
	Sweet's syndrome
	Bowel-associated dermatosis-arthritis syndrome
Miscellaneous	Epidermolysis bullosa acquisita
	Clubbing
	Vitiligo
	Psoriasis
	Secondary amyloidosis
	Alopecia areata

show perianal lesions before gastrointestinal complaints.^{12,13} The majority of our patients with Crohn's disease (6 of 8), as well as our 1 patient with ulcerative colitis, were noted to have perianal lesions before gastrointestinal symptoms. It is interesting to note that the 2 patients with Crohn's disease who did not have perianal lesions had pyoderma gangrenosum as their initial finding. Of the patients with perianal lesions, in only 2 (patients 8 and 9) was the perianal lesion the presenting complaint. This suggests that perianal lesions may often be present before gastrointestinal complaints but are less often brought to the attention of the physician, especially in adolescent boys.

Although not as well documented, oral lesions associated with IBD are relatively common, occurring in 6% to 20% of patients.¹⁴ When present, they are the presenting sign/symptom in approximately one half of cases.^{1,4,15-17} In addition, more recent

TABLE 3. Oral Lesions in IBD

Specific
Orofacial granulomatosis (granulomatous cheilitis)
Cobblestoning
Mucosal tags
Deep, linear ulcers with hyperplastic folds
Pyostomatitis vegetans
Nonspecific
Aphthous ulcers
Angular cheilitis
Labial/facial edema
Gingivitis
Gingival erythema/edema

reviews have found an increased prevalence of various oral lesions in IBD, particularly in children. Barnard and Walker-Smith found that 80% of pediatric patients with Crohn's disease and 41% of children with ulcerative colitis had oral lesions in their series of patients.¹⁸ In reviews by Pittock et al¹⁹ and Plauth et al,⁴ 48% and 66% of patients with Crohn's disease, respectively, were found to have oral manifestations, with an increased prevalence in children.

A variety of specific and nonspecific oral lesions can occur (Table 3). Differences in the percentage of patients with IBD described with oral lesions may relate to specific versus nonspecific oral findings reported. Aphthous ulcers are considered by many to be nonspecific, as they can be seen in up to 20% of the general population; however, aphthae are usually more extensive and persistent when associated with IBD.¹⁵ The descriptive term "orofacial granulomatosis" has been used for any granulomatous process of unknown etiology involving the oral cavity,¹⁶ which includes disorders previously described as granulomatous cheilitis and partial Melkersson-Rosenthal syndrome. Orofacial granulomatosis is a common manifestation in children with IBD and is typified by recurrent or persistent swelling of the lips, cheeks, gingiva, or oral mucosa with characteristic noncaseating granulomas on histologic examination. Many patients with orofacial granulomatosis do eventually develop gastrointestinal disease consistent with Crohn's disease.^{20,21} "Cobblestoning" refers to nodular granulomatous swellings that result in a cobblestone appearance of the oral mucosa, particularly on the labial and buccal mucosa. Along with mucosal tags, cobblestoning is highly suggestive of Crohn's disease. Pyostomatitis vegetans, on the other hand, is more characteristic of ulcerative colitis. It is characterized by multiple pustules, erosions, and ulcers on a diffuse erythematous background with vegetations or folding of the gingival and buccal mucosa. Deep, linear ulcers surmounted by hyperplastic folds occur in the gingival sulci and are also specific for IBD.

Genital findings associated with IBD are also more common in Crohn's disease and in children.¹ Genital involvement includes vulvar swelling, skin tags, pustules, abscesses, fistulas, fissures, ulcerations, and vaginal discharge.²² Penile and scrotal lesions are less common and include subcoronal ulcers as well as penile and scrotal edema.²³ Twenty-five percent of genital Crohn's disease presents before gastrointestinal complaints.¹

Although there are few cases reported in the pediatric literature, mucocutaneous lesions presenting as the initial sign of IBD is relatively common and can be an important clue in making the diagnosis of IBD before the development of gastrointestinal symptoms. We have identified 9 pediatric patients with asymptomatic IBD presenting with mucocutaneous lesions. The majority of these patients had oral and/or perianal lesions. Because oral disease, in general, is uncommon in children, we believe that IBD is a common etiology for persistent oral lesions in the pediatric population. Children and adolescents with unexplained oral mucous membrane lesions such as lip/mucosal swelling, gingival hyperplasia, cobblestoning of the oral mucosa, or deep linear ulcerations should have a good history taken regarding gastrointestinal symptoms, fever, and weight loss as well as an examination of the rectal and genital mucosa to seek other mucocutaneous clues of IBD that may not be mentioned to the physician. We would also recommend additional work-up including complete blood count, iron levels, ESR, albumin, occult blood in the stool, and serial endoscopies with biopsies to aid in the diagnosis if suspicions are high.

REFERENCES

- Ploysangam T, Heubi JE, Eisen D, Balistreri WF, Lucky AW. Cutaneous Crohn's disease in children. *J Am Acad Dermatol.* 1997;36:697-704
- McCallum DI, Kinmont PD. Dermatological manifestations of Crohn's disease. *Br J Dermatol.* 1968;80:1-8
- Greenstein AJ, Janowitz HD, Sachar DB. The extra-intestinal complications of Crohn's disease and ulcerative colitis: a study of 700 patients. *Medicine (Baltimore).* 1976;55:401-412
- Plauth M, Jenss H, Meyle J. Oral manifestations of Crohn's disease. An analysis of 79 cases. *J Clin Gastroenterol.* 1991;13:29-37
- Gregory B, Ho VC. Cutaneous manifestations of gastrointestinal disorders. Part II. *J Am Acad Dermatol.* 1992;26(3 pt 2):371-383
- Burgdorf WH. Cutaneous manifestations of Crohn's disease. *J Am Acad Dermatol.* 1981;5:689-695
- Apgar JT. Newer aspects of inflammatory bowel disease and its cutaneous manifestations: a selective review. *Semin Dermatol.* 1991;10:138-147
- Powell FC, Perry HO. Pyoderma gangrenosum in childhood. *Arch Dermatol.* 1984;120:757-761
- Paller AS, Sahn EE, Garen PD, Dobson RL, Chadwick EG. Pyoderma gangrenosum in pediatric acquired immunodeficiency syndrome. *J Pediatr.* 1990;117:63-66
- Gilman AL, Cohen BA, Urbach AH, Blatt J. Pyoderma gangrenosum as a manifestation of leukemia in childhood. *Pediatrics.* 1988;81:846-848
- Mir-Madjlessi SH, Taylor JS, Farmer RG. Clinical course and evolution of erythema nodosum and pyoderma gangrenosum in chronic ulcerative colitis: a study of 42 patients. *Am J Gastroenterol.* 1985;80:615-620
- Baker WN, Milton-Thompson CJ. The anal lesion as the sole presenting symptom of intestinal Crohn's disease. *Gut.* 1971;12:865
- Lebwohl M, Lebwohl O. Cutaneous manifestations of inflammatory bowel disease. *Inflamm Bowel Dis.* 1998;4:142-148
- Basu MK, Asquith P. Oral manifestations of inflammatory bowel disease. *Clin Gastroenterol.* 1980;9:307-321
- Berstein ML, McDonald JS. Oral lesions in Crohn's disease: report of two cases and update of the literature. *Oral Surg Oral Med Oral Pathol.* 1978;46:234-245
- Wiesenfeld D, Ferguson MM, Mitchell DN, et al. Oro-facial granulomatosis—a clinical and pathological analysis. *Q J Med.* 1985;54:101-113
- Williams AJ, Wray D, Ferguson A. The clinical entity of orofacial Crohn's disease. *Q J Med.* 1991;79:451-458
- Barnard KM, Walker-Smith JA. The prevalence of oral manifestations of inflammatory bowel disease in a paediatric population [abstract]. *J Dent Res.* 1994;73:A388
- Pittock S, Drumm B, Fleming P, et al. The oral cavity in Crohn's disease. *J Pediatr.* 2001;138:767-771

20. Scully C, Cochran KM, Russell RI, et al. Crohn's disease of the mouth: an indicator of intestinal involvement. *Gut*. 1982;23:198–201
21. Bogenrieder T, Rogler G, Vogt T, Landthaler M, Stolz W. Orofacial granulomatosis as the initial presentation of Crohn's disease in an adolescent. *Dermatology*. 2003;206:273–278
22. van de Scheur MR, van der Waal RI, van der Waal I, Stoof TJ, van Deventer SJ. Ano-genital granulomatosis: the counterpart of oro-facial granulomatosis. *J Eur Acad Dermatol Venereol*. 2003;17:184–189
23. Poon KS, Gilks CB, Masterson JS. Metastatic Crohn's disease involving the genitalia. *J Urol*. 2002;167:2541–2542

Asymptomatic Inflammatory Bowel Disease Presenting With Mucocutaneous Findings

Sheila S. Galbraith, Beth A. Drolet, Subra Kugathasan, Amy S. Paller and Nancy B. Esterly

Pediatrics 2005;116:e439; originally published online August 11, 2005;
DOI: 10.1542/peds.2004-2281

Updated Information & Services	including high resolution figures, can be found at: http://pediatrics.aappublications.org/content/116/3/e439.full.html
References	This article cites 22 articles, 4 of which can be accessed free at: http://pediatrics.aappublications.org/content/116/3/e439.full.html#ref-list-1
Subspecialty Collections	This article, along with others on similar topics, appears in the following collection(s): Gastrointestinal Tract http://pediatrics.aappublications.org/cgi/collection/gastrointestinal_tract
Permissions & Licensing	Information about reproducing this article in parts (figures, tables) or in its entirety can be found online at: http://pediatrics.aappublications.org/site/misc/Permissions.xhtml
Reprints	Information about ordering reprints can be found online: http://pediatrics.aappublications.org/site/misc/reprints.xhtml

PEDIATRICS is the official journal of the American Academy of Pediatrics. A monthly publication, it has been published continuously since 1948. PEDIATRICS is owned, published, and trademarked by the American Academy of Pediatrics, 141 Northwest Point Boulevard, Elk Grove Village, Illinois, 60007. Copyright © 2005 by the American Academy of Pediatrics. All rights reserved. Print ISSN: 0031-4005. Online ISSN: 1098-4275.

American Academy of Pediatrics

DEDICATED TO THE HEALTH OF ALL CHILDREN™

