

Heart Murmurs

Victor Menashe, MD*

Author Disclosure
Dr Menashe did not disclose any financial relationships relevant to this article.

Introduction

Heart murmurs are heard commonly in infants, children, and adolescents. Approximately 50% to 70% of individuals seen for school or sports preparticipation examinations have a heart murmur. Indeed, a murmur is heard in most children at one or more of their examinations. Because most murmurs are innocent (ie, normal), it is important to differentiate those that are a manifestation of cardiac disease. Unfortunately, skills of physical diagnosis seem to be waning, as they are replaced by “advances” in medical technology. This so-called “hyposkillia” should not go unlamented because it has occurred among the caregiving community at great expense, not only in terms of economic cost, but also at a cost to the excellent physician-patient relationship that is established when the history and physical examination are performed well. (1)

This review focuses on the evaluation of cardiac murmurs within the context of a comprehensive history and physical examination, paying particular attention to the cardiovascular examination. The cardiovascular history should include notations regarding gestation, family history, neonatal status, growth and development, and feeding patterns for infants. For older children, the history should include the presence of palpitations, chest pain, lightheadedness or syncope, and activity level, remembering that the range of activity in healthy children is great and that children who have congenital heart defects generally have not experienced a decline in their exercise tolerance. Positive findings in any of these areas should increase suspicion that a murmur might be pathologic.

Cardiac Examination

The cardiac examination includes observation (Table 1), palpation (Table 2), and auscultation. Although observation of all patients precedes palpation and auscultation, whether to palpate or auscultate depends on the particular child being examined. Pediatric examinations frequently are not sequential, but rather proceed based on random opportunities offered by an often reluctant child.

Auscultation is a skill that is easy to acquire but also easy to lose. As with all skills, good auscultation requires an understanding of fundamental concepts and repetitive practice, as well as thinking about what is heard. The listener must have a stethoscope that transmits sound with minimal distortion. Typically, a good stethoscope has tubing with an inner diameter that is uniform from chest piece to earpiece and is no more than 18 inches in length. The earpieces should fit comfortably without air leaks. The chest piece preferred by many cardiologists is the bell, which is best for lower frequency sounds when held lightly on the chest. For higher frequency sounds, it can be pressed more firmly against the chest to become diaphragm-like.

Before the examination begins, both the caregiver and the patient must be comfortable. This position of comfort may be with the patient on the parent’s lap or on an examination table. If the child is on a lap, it is more comfortable for the examiner to sit during auscultation; if the patient is on an examining table, it should be large enough for the child to sit and lie easily and have a headboard whose angle can be changed to evaluate the venous pressure in the neck vessels. Distracting noises must be eliminated.

Most importantly, the auscultator must be knowledgeable about the characteristic sounds of the heart (both normal and pathologic). The presence or absence of all the possible cardiac sounds must be considered during each examination. Accordingly, every examination is an excellent opportunity to practice all the skills of auscultation and the events of the cardiac cycle.

*Division of Pediatric Cardiology, Oregon Health & Science University, Portland, Ore.

Table 1. **Observation**

- Signs of a syndrome
- Central cyanosis
- Breathing pattern
- Precordial activity
- Digital clubbing
- Neck vein distension

Heart Sounds

The best method of remembering the characteristics of heart sounds is to understand their positions within the cardiac cycle (Figure). The first heart sound (S_1) is a manifestation of atrioventricular valve closure and may be split due to asynchrony when the tricuspid valve closure is slightly delayed. The second sound (S_2) is the result of closure of the aortic and pulmonary valves. These sounds often are heard separately (A_2 and P_2). P_2 normally is delayed because of reduced impedance in the pulmonary vascular bed, the so-called “hangout” time. The third heart sound is heard with rapid filling of the ventricles and often is heard normally in children. The fourth heart sound is pathologic and heard in patients who have relatively stiff ventricles (it is heard only with sinus rhythm).

Systolic murmurs are classified as pansystolic (holosys-

Table 2. **Palpation**

Precordium

- Lifting or displaced point of maximal impulse, suggesting hypertrophy (eg, stenotic lesion, hypertrophic cardiomyopathy)
- Hyperdynamic, suggesting high volume flow (eg, left-to-right shunts)

Arterial Pulses

- Bounding—relating a wide pulse pressure, associated with aortic run-off (patent ductus arteriosus or aortic regurgitation; also consider hyperthyroidism or arteriovenous fistula)
- Decreased, hard-to-detect pulses may be associated with severe aortic stenosis
- Synchrony and equality of upper and lower extremity pulses for evaluation of coarctation of the aorta; palpation of right brachial and femoral pulses, making certain that the right and left brachial pulses also are equal

Abdomen

- Size of liver and spleen and pulsation of the liver

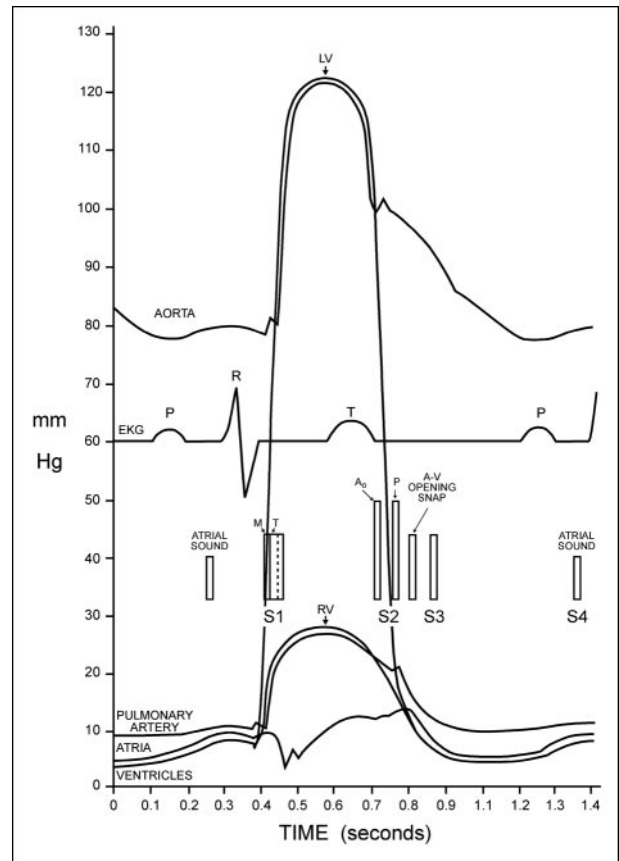


Figure. Events of the cardiac cycle relating the pulse pressure curves of the ventricles, the great arteries, and the atria with the electrocardiogram and heart sounds. S_1 (noted as M and T) is the sound of closing mitral and tricuspid valves as the ventricular pressure exceeds the atrial pressure. S_2 occurs with closure of the semilunar valves as the ventricular pressure falls below the respective diastolic pressure in the aorta and pulmonary artery. The third heart sound in diastole is related to the rapid filling of the ventricle. A fourth heart sound is presystolic and associated with atrial systole. Ejection clicks occur as the ventricular pressure exceeds the great artery pressure. (This sound has been likened to a sail catching wind.) The opening snap noted in the figure is the sound heard with stenotic and calcified atrioventricular valves, particularly the mitral valve, as the ventricular pressure falls below the atrial pressure. With more severe stenosis, this sound becomes closer to that of S_2 and can be mistaken for a split S_2 . Reprinted with permission from *Cardiovascular Sound in Health and Disease*. Philadelphia, Pa: Williams & Wilkins; 1958:115.

tolic) or ejection. Pansystolic murmurs begin with the first sound (ie, with the onset of blood flow) during isometric contraction of the ventricle into either of the atria (atrioventricular valve regurgitation) or lower pressure right ventricles (through a ventricular septal defect).

Ejection murmurs begin after the first sound, have a crescendo-decrescendo quality, and are related to flow into the great vessels.

Diastolic murmurs are defined as immediate, early or medium, or late. Immediate murmurs occur immediately after semilunar valve closure, early or mid-diastolic murmurs are associated with the rapid filling phase of the ventricle, and late diastolic murmurs are associated with atrial systole.

The intensity of murmurs usually is classified on a scale of 1 to 6, although grades 5 and 6 are used very rarely:

- Grade 1: Barely audible
- Grade 2: Audible and constant
- Grade 3: Loud with no accompanying palpable thrill
- Grade 4: Loud with an accompanying thrill
- Grade 5: Heard with the stethoscope just touching the chest
- Grade 6: Heard with the stethoscope off the chest

Distinguishing Between Innocent and Pathologic Murmurs

Most often, the physical examination alone permits the caregiver to determine if heart disease is present. The vast majority of murmurs are innocent, displaying the following uniform characteristics:

- Early systolic ejection
- Short duration
- Low intensity (grade 2 or 1)
- Vibrating (or musical) quality

Innocent Murmurs

The Still murmur is perhaps the most common innocent murmur in children and is characterized by a musical or vibratory quality at the mid-to-lower sternal border and toward the apex. It is believed to be caused by turbulence in the left ventricular outflow tract. The pulmonary systolic ejection murmur can be differentiated from atrial septic defects by the physiologic splitting of S_2 or pulmonary valve stenosis by the presence of a normal S_2 and the absence of an ejection click. The precordium is not hyperdynamic, and there is no diastolic murmur.

The supraclavicular bruit is heard above the clavicles and, to a much lesser extent, below the clavicle. This sound is due to turbulence in the carotid artery, most often the right, resulting from the systolic ejection streaming into this vessel. This murmur sometimes is associated with a thrill palpable over the carotid. It is differentiated from the murmur of valvar aortic stenosis by the lack of an ejection click, normal second sounds, and the location where it is heard loudest.

Peripheral pulmonary artery stenosis of the newborn is a mid-systolic murmur of low intensity heard at the base of the heart, in the axillae, and over the back, with a split S_2 of normal intensity. The sound likely is related to the acute take-off angle of the branch pulmonary arteries of the newborn, which remodel over time with increased pulmonary blood flow, leading to the murmur's disappearance, usually in 3 to 6 months.

Venous hum is a systolic/diastolic murmur heard in the infraclavicular region (usually right-sided) in a sitting or standing patient. Disappearance when the patient lies down or when the examiner applies gentle pressure over the jugular vein is diagnostic. The murmur is caused by blood cascading down the jugular vein. It typically is louder in diastole as the atrium empties.

Pathologic Murmurs

Pathologic murmurs, if systolic, generally are longer and louder than innocent murmurs. All diastolic murmurs (with exception of the venous hum) are pathologic, as are all pansystolic murmurs. Pansystolic murmurs occur when there is flow from a high-pressure chamber into a low-pressure chamber. Cardiac malformations associated with pansystolic murmur are ventricular septal defect (VSD), mitral regurgitation (MR), tricuspid regurgitation (TR), and patent ductus arteriosus (PDA), although the murmur of the PDA is a crescendo murmur during systole, differing from the even amplitude murmurs of VSD, TR, and MR. MR in children is seen most commonly in patients who have atrioventricular canal defects both pre- and postoperatively or mitral valve prolapse, but also can be present in patients who have acute rheumatic fever. The decrescendo diastolic murmur of aortic regurgitation also may be heard as a manifestation of acute rheumatic fever.

Pathologic ejection murmurs usually are louder and longer than innocent ejection murmurs. Ejection murmurs may be differentiated further by the presence of other auscultatory or physical findings. Is there an ejection click? Is S_2 widely split? Does the S_2 split move? Is S_2 moving normally? Is the heart hyperdynamic? Are the neck veins distended? Are peripheral pulses normal? Is there a diastolic murmur?

Ejection clicks are heard with stenosis of either the aortic or pulmonary valve if the valve is mobile. Clicks are sharp sounds heard after S_1 . They sometimes sound like a split S_1 except for their crisper quality, greater intensity, and association with the ejection murmurs of aortic or pulmonary stenosis.

Evaluation of S_2 is critical in the evaluation of heart murmurs. The clinician usually can hear S_2 split in chil-

dren, but it often is difficult to discern whether the split has the normal movement of narrowing with expiration and widening with inspiration. For children older than 3 or 4 years of age, the clinician may be able to regulate their breathing by leading them with his or her hand, raising the hand for inspiration and lowering the hand for expiration. This maneuver slows and quiets respirations to provide a clearer definition of splitting.

Diastolic murmurs are, perhaps, the most difficult murmurs to appreciate. They frequently are low-intensity and may be either high- or low-pitched. Mitral or tricuspid diastolic murmurs are heard best with the bell placed lightly without air leaks. Tricuspid murmurs occur over the xiphoid process or to the right of the sternum in the fourth intercostal space. Mitral diastolic murmurs may be audible from the left fourth intercostal to the cardiac apex. A mitral diastolic flow murmur often is associated with VSDs, whereas a tricuspid diastolic flow murmur may be heard in patients who have atrial septal defects. Both are caused by relatively increased blood flow across these valves due to a large left-to-right shunt. The diastolic murmur of mitral stenosis caused by rheumatic heart disease is extremely rare today.

Pulmonary valve regurgitation occurs commonly after repair of tetralogy of Fallot. Its associated murmur is a low-pitched, rumbling, decrescendo sound following S_2 . When heard in association with Eisenmenger syndrome, it is a high-pitched murmur similar to the murmur of aortic valve regurgitation.

Aortic valve regurgitation is one of the more difficult murmurs to appreciate. It is a decrescendo, low-intensity but high-pitched murmur and often is mistaken for a breath sound. One method to confirm the murmur is to listen in an area that clearly has no murmur in diastole and move back and forth from that area to the area where the murmur is suspected.

Auscultation of the Newborn

Auscultation in the newborn can be challenging, but with practice, the clinician can appreciate the heart sounds and murmurs with greater assurance. The rapid heart rate makes it difficult to appreciate splitting of the second sound, which may be heard only as a prolongation of the second sound. With careful listening and practice, the clinician can distinguish this slightly prolonged second sound from the discrete, crisp, and loud second sound that is associated with the severe stenosis or atresia of one of the semilunar valves or with pulmonary hypertension.

Murmurs in the newborn are common. The clinician interprets a newborn murmur essentially as he or she

interprets murmurs in infants and children. However, it is worth remembering that the character of the murmur associated with VSD and PDA varies with the decrease in the pulmonary vascular resistance, increasing in duration and intensity as the left-to-right shunt increases. The VSD murmur becomes a pansystolic murmur, and the PDA becomes continuous.

Summary

Evaluation of heart murmurs requires an understanding of basic cardiac physiology relating to the events of the cardiac cycle. Innocent and pathologic cardiac murmurs often can be differentiated with only a comprehensive history and skilled auscultation and without ancillary studies. Although easily acquired, auscultation is a skill that requires continued practice. Innocent murmurs are common, and parents need to be assured of their benign nature and the reasons they occur.

There is no substitute for development of a skill other than through practice. Just as in sports, so it is with auscultation. We are fortunate that today's practice of auscultation is not confined to listening to patients. Digital recordings of heart sounds have a much improved fidelity, [Click here for a Data Supplement comprising 16 heart murmurs] and listening to these recordings does improve auscultatory skill. In a recent study, Barrett and colleagues found that having medical students listen to recordings multiple times improved their skills such that they could recognize 80% of the heart sounds compared with their pretest ability of recognizing only 30%. (2) Therefore, with only a few minutes of practice each day, thinking about what to listen to and for, the clinicians can become skilled in the art of auscultation.

ACKNOWLEDGMENT. Special thanks and appreciation to Michael Silberbach, MD, for his critical reading of and suggestions for this article.

References

1. Fred HL. Hyposkillia: deficiency of clinical skills. *Tex Heart Inst J.* 2005;32:255–257
2. Barrett MJ, Lacey CS, Sekara AE, Linden EA, Cracely EJ. Mastering cardiac murmurs: the power of repetition. *Chest.* 2004; 126:470–475

Suggested Reading

- Biancaniello T. Innocent murmurs: a parent's guide. *Circulation.* 2004;109:e162-e163
- McNamara DG. Value and limitations of auscultation in the management of congenital heart disease. *Pediatr Clin North Am.* 1990;37:93–113
- Rosenthal A. How to distinguish between innocent and pathologic murmur in childhood. *Pediatr Clin North Am.* 1984;31: 1229–1240