

# Rectal Prolapse: 17-Year Experience With the Posterior Repair and Suspension

By Keith W. Ashcraft, John L. Garred, Thomas M. Holder, Raymond A. Amoury, Ronald J. Sharp, and J. Patrick Murphy  
Kansas City, Missouri

● Using a posterior repair and rectal suspension procedure for those patients who need surgical treatment of rectal prolapse, we have treated 46 patients over a period of 17 years at Children's Mercy Hospital in Kansas City, MO. One patient with caudal dysgenesis died of multiple congenital anomalies following two unsuccessful attempts at posterior repair and suspension. Four patients developed a recurrence afterwards, which was found to be due to sigmoid intussusception and, presumably, had played a major part in their original prolapse. Two of these required resection, one from the transanal approach and one from the transabdominal approach. One resolved spontaneously and another is as yet unresolved. Three patients had minor mucosal prolapse that was transient and two patients had extrusion of silk sutures but continued to have a very satisfactory result. Overall, 42 patients had satisfactory resolution of their rectal prolapse. Three of the four patients who had unsatisfactory results had associated anomalies that contributed to their poor outcome.

© 1990 by W.B. Saunders Company.

**INDEX WORDS:** Rectal prolapse.

**T**HE PROBLEM of rectal prolapse in children was very nicely described by Lockhart-Mummery in 1939.<sup>1</sup> He attributed the prolapse that occurs in young children to malnutrition and careless nursing, but realized that it might also occur following infectious diarrhea or a wasting illness such as whooping cough or measles. He stated that improvement in nutrition was often the only therapy necessary to correct the problem, although attention to the problem of constipation and straining was necessary for a period of several months. He felt that the child should avoid sitting on the "chamber or lavatory seat" because of propensity to aggravate the prolapse and instead the child should relieve himself by squatting over a tray or a newspaper. Failure of this conservative therapy to relieve the problem sometimes necessitated operative treatment.

Lockhart-Mummery's operative treatment for prolapse in children included linear cauterization of the prolapsed rectum in four quadrants from the anal

margin out to the furthest extent of the prolapse. The mass, having been cauterized, was then returned to its normal position and the same stooling protocol continued for a month or more. Should this fail to relieve the prolapse, injection of 4 mL of 5% phenol in almond oil with a little menthol added was recommended to be performed under general anesthesia, creating a weal just under the mucous membrane at three or four points around the rectum. This material induced such an inflammatory response that prolapse hopefully would not recur.

Variations on these two treatments were continued until Altemeier et al described their perineal approach for repair of rectal prolapse, which amounted to an anterior closure of the pelvic diaphragm and transanal resection of the prolapsed segment with anastomosis. A 19-year experience with this procedure was reported in 1970 with a very low morbidity and no mortality in a generally very elderly population.<sup>2</sup> The repair of Ripstein and Lauter,<sup>3</sup> which consisted of a transabdominal rectal suspension, similarly addressed the problem of prolapse as being an intussusception. It seems clear that intussusception leads to herniation of the muscular hiatus through which the rectum traverses the pelvis, which in turn allows further and more extensive prolapse. The differentiation of sigmoid intussusception from rectal intussusception is difficult.

In 1976 we reported our experience with four patients having a posterior levator repair and suspension of the rectum for rectal prolapse.<sup>4</sup> This report carries that experience on to 17 years and 46 patients, 42 of whom were available for follow-up.

## MATERIALS AND METHODS

### *Operative Procedure*

With the patient in the jackknife position, a small Hegar dilator is placed into the rectum to allow easy palpation of the rectum through the wound. The buttocks are spread, and a midline incision is made from the coccyx extending about halfway to the anus. This incision is deepened to expose the coccyx, which is then removed. The retrorectal space is thus entered and by blunt dissection posterior to the rectum, the marked stretching of the levator musculature becomes apparent. A right angle retractor is used to lift the levator mechanism away from the rectum so that the muscle complex that surrounds the rectum can be narrowed by permanent sutures posteriorly. Permanent sutures are used, taking care not to enter the lumen of the rectum to attach the reduced anal canal to the muscle complex laterally (Fig 1). The muscle complex is then narrowed in the midline posteriorly so that it is very snug about the rectum. All slack is removed in the rectum by pulling its posterior wall cephalad.

---

*From the Department of Surgery, The Children's Mercy Hospital, Kansas City, MO.*

*Presented at the 38th Annual Meeting of the Surgical Section of the American Academy of Pediatrics, Chicago, Illinois, October 21-23, 1989.*

*Address reprint requests to Keith W. Ashcraft, MD, Department of Surgery, The Children's Mercy Hospital, 2301 Gillham Rd, Kansas City, MO 64108-9898.*

© 1990 by W.B. Saunders Company.

0022-3468/90/2509-0015\$03.00/0

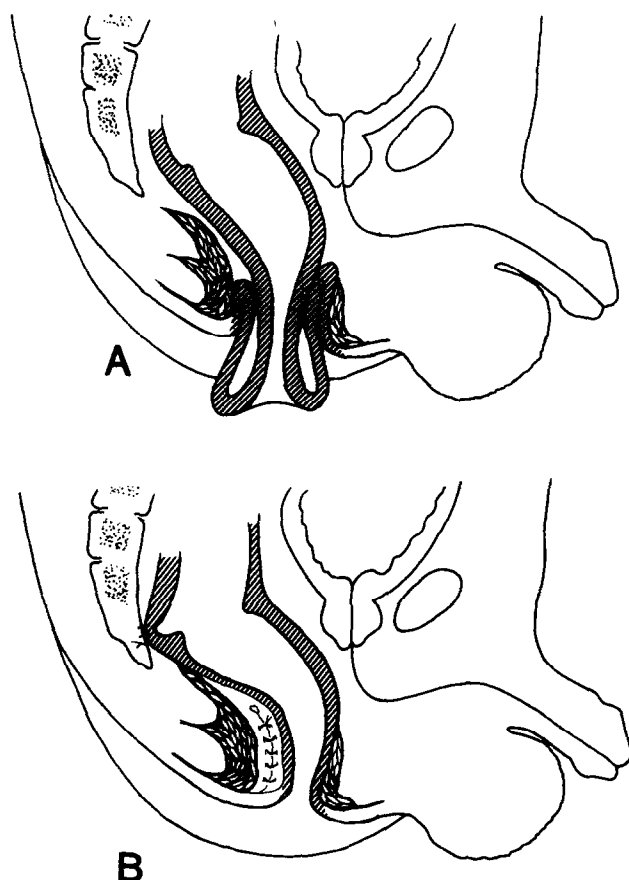


Fig 1. (A) Cutaway view of the prolapse. Because of the excessive amount of tissue coming through the anal canal, the levator mechanism is dilated. (B) The closure of the muscle complex behind the rectum narrows the canal, and fixation of the rectum to the cut edge of the coccyx further prevents prolapse.

The taut rectum is sutured to the cut edge of the sacrum (from which the coccyx had been removed) with three permanent sutures that will prevent the rectum from falling again through the anus. We feel that it is not necessary to either reduce the peritoneal reflection anteriorly or to try to suspend the rectum anteriorly in any way if adequate suspension is done posteriorly. The wound is then closed and the patient, unless there are mitigating circumstances, is discharged. Although we have not performed the procedure by splitting this muscle complex, the experience of the posterior sagittal anorectoplasty would suggest that this would be entirely feasible, allowing easier access to the distal most portion of the muscle complex. This should allow the anal walls to be fixed to the muscle complex with excellent exposure.

The postoperative management consists of stool softeners for 1 to 2 weeks and avoiding letting the child sit for any extended period of time on the stool. It is not necessary for them to defecate on a newspaper.

### Patient Material

Since 1972 we have treated 46 patients surgically by this technique, 42 of whom were available for follow-up for periods of 2 months to 10 years. The patients age ranged from 3 months to 10 years, with a median of 3 years. The median follow-up was 2 years. The median duration of prolapse prior to repair was 4 months, with a range from 1 week to 4 years.

## RESULTS

### Associated Lesions

Five patients had myelodysplasia and eight other patients had associated disorders (Table 1). There was only 1 patient with cystic fibrosis. Although early on in the series we performed sweat chloride determinations on all the patients who had rectal prolapse, none were found to be positive. Recently one 3-year-old girl examined for prolapse of short duration was found to have a positive sweat test. She has not yet undergone surgery.

Of the 42 patients who were followed adequately, 34 had an excellent result with no further prolapse. Three patients had mild mucosal prolapse of short duration postoperatively, which was probably due to residual edema and was not a long-lasting complication. All have resolved.

Four patients had intussusception following satisfactory suspension of their rectum, suggesting that the lead point on the initial intussusception was much higher than we had anticipated. One resolved spontaneously. Three are considered failures. One of these required a resection from below similar to Altemeier's procedure. Another required a transabdominal sigmoid resection, and the fourth is under observation. These four patients illustrate the importance of delineating sigmoid intussusception from rectal prolapse. The two may be intimately related, as Altemeier has shown. In the pediatric patient with prolapse of short duration, this combination is less likely. Every effort should be made to determine the depth of the sulcus prior to reduction of the prolapse but this is not always possible. The barium study with a "defecating" view might be helpful. The barium study showed on review that the early filling film resembled the "coiled spring" appearance of intussusception. This last patient awaits resolution of his continued prolapse. Three of the four intussusception patients had associated lesions—trisomy 9, William's syndrome, and Hirschsprung's disease (Table 1).

There was one patient whose condition did not improve after the operation. He was a boy with caudal dysgenesis who suffered prolapse continuously. At age 5 months he underwent posterior repair and suspension, although there was virtually nothing posterior to the rectum that could be brought together. The prolapse immediately recurred. A second attempt 2 months later was similarly unsuccessful. He died at the age of 10 months of multiple congenital defects.

### Complications

In addition to the four sigmoid intussusceptions, two of which required resection, two patients had extrusion of some of the silk sutures through the midline wound. Although these sutures extruded, there was no recur-

Table 1. Rectal Prolapse: Posterior Repair (1972-1989)

Associated Lesions	No. of Patients
Myelodysplasia	5
Caudal dysgenesis*	1
Exstrophy of bladder	1
Trisomy 9*	1
Transposition (Senning)	1
Cystic fibrosis	1
VATER, MMR	1
Hirschsprung's disease (previous Soave)*	1
William's syndrome*	1

Abbreviations: VATER, MMR, vertebral, anorectal, tracheoesophageal, radial anomalies with mental motor retardation.

\*Operative failures.

rence of the prolapse and ultimately they had an excellent result.

### DISCUSSION

Although rectal prolapse is often dismissed as being an inconsequential lesion, it is sometimes painful, sometimes produces bleeding, and is certainly a distress to the parent. Satisfactory resolution of the problem often can be accomplished nonoperatively, but in those instances where the child simply cannot be managed by the parents or where prolapse has been recurrent for several months without improvement,

surgical treatment is deemed necessary. Although as recently as a few years ago it was suggested in one of the textbooks of pediatric surgery that injection of 5% phenol in peanut oil was the procedure of choice,<sup>5</sup> it would seem to us not to be the ideal operative procedure. Even the injection of other forms of sclerosing solutions such as 25% glucose or 30% saline require anesthetic in the child of the age to be treated in this manner.<sup>6</sup> We believe that the posterior suspension and levator repair is a very anatomically sound approach. It seems that this is a much more physiological, much more direct attack on the problem and one that has been demonstrated now to have held up over the years.

### REFERENCES

1. Lockhart-Mummery JP: Surgical procedures in general practice. *Br Med J* 1:345-347, 1939
2. Altmeier WA, Culbertson WR, Schowengerdt C, et al: Nineteen year's experience with the one-stage perineal repair of rectal prolapse. *Ann Surg* 173:993-1006, 1971
3. Ripstein CB, Lauter B: Etiology and surgical therapy of massive prolapse of the rectum. *Ann Surg* 157:259-264, 1963
4. Ashcraft KW, Amoury RA, Holder TM: Levator repair and posterior suspension for rectal prolapse. *J Pediatr Surg* 12:241-245, 1977
5. Leape LL: Other disorders of the rectum and anus, in Welch KJ, Randolph JG, Ravitch MM, et al (eds): *Pediatric Surgery*. Chicago, IL, Year Book, 1986, pp 1042-1043
6. Kay NRM, Zachary RB: The treatment of rectal prolapse in children with injections of 30 percent saline solution. *J Pediatr Surg* 5:334-337, 1970

## Discussion

*D. Stephens (Melbourne, Australia):* I thought the idiopathic prolapse of intussusception of the rectum is quite different from the neuropathic types, which you described in your series, or those associated with exstrophy of the bladder where there's some opening out of the levator ani. I think that the neuropathic types resemble very much the adult type of prolapse. They never get better on their own; they get worse, if anything, and I think they should clearly be differentiated from the idiopathic type that occurs in children. The latter all get better in time, what ever you do, and it's just a question of hurrying it up in some. I think the method you described does hurry it up and it does cure it in a number of patients. When I was at Great Ormand Street, training with Dennis Brown, he always used to put a small perianal chromic catgut suture around the rectum, which effected a cure in most cases. The suture dissolved out after 3 weeks or so; it was a pretty thick suture, performed of course, with its own special needle, which was almost  $\frac{3}{4}$  of a circle. And there are other conservative methods of treating the idiopathic type, which we all know and to which the prolapse responds. I would say that this is an intussusception, the idiopathic type is an intussusception, and I think that the neuropathic type is a prolapse. The idiopathic type always has a little fornix that you can put your finger up around. The anus is held by the coattails of the levator ani and that's the anatomical

reason for the fact that the anus itself does not prolapse. The rectum comes down and prolapses through the anus and that's the difference from the prolapse in the neuropathic type of the adult. It was thought, in the old days, that it was a mucosal prolapse only, but work by Robert Fowler showed quite differently. Of course, if you use the injection technique, it has to be, I think, outside the bowel wall. I believe this operation is a clear cut anatomical type of operation, and is probably suitable for all types.

*K. Ashcraft (response):* I would agree with you, Douglas, that the idiopathic prolapse will go away by itself, given enough time, but patients and parents are not anxious to put up with it for a great deal of time. The average length of prolapse in the patients we treated was about 4 months. Anything you can do, including Thiersch wiring or using the chromic catgut in a circumferential perianal manner, that will keep the rectum in its place while its attachments resume their normal position, will work. However, it requires an anesthetic to perform these proceedings, and it seems to us a little more logical to produce an instant cure rather than putting in a wire and hoping.

*W. Chwals (Winston-Salem, NC):* When I was in Los Angeles, we reported a 19-year experience with idiopathic rectal prolapse that was not associated with any anatomical or neurological anomalies. We performed operative repair using a mucosal sleeve resec-

tion. The postoperative follow-up, which extended out to 19 years, indicated that there were no strictures, no incontinence, and no recurrences during that period of time. Sexual function in one individual, who was 32 years old, was preserved. This experience would seem to indicate that, in the absence of anatomical or neurological anomalies associated with the prolapse, a reconstruction of the sphincter mechanism is not necessary.

*K. Ashcraft (response):* We are not rebuilding a sphincter; we are just narrowing the rectal canal so that things don't herniate or prolapse through it.

*T. Lobe (Memphis, TN):* If you have a prolapse of a lesser degree, do you try a lesser procedure first before

you go to this type of reconstruction? Clearly, you do have to use general anesthesia for either injection or your operation, but your operation still is a bigger procedure than injection. If you have a minor degree of prolapse, will you try injection first or some lesser procedure and then if that fails once, go straight on to your reconstruction?

*K. Ashcraft (response):* The answer to your question is no. We haven't done any injections and don't intend to. As Douglas Stephens said, it's a full-thickness herniation or prolapse or intussusception, whatever you want to call it. It seems pretty indirect to try to generate some sort of inflammatory response when you can do a nice clean surgical procedure.